

**REACTIVATION AND RESOLUTION IN SHINGLES: A  
COMPREHENSIVE REVIEW OF HERPES ZOSTER**

**K. Arunkumar<sup>1\*</sup>, P. Nandhitha<sup>2</sup>, T. Sampath Kumar<sup>3</sup>, C. Jothimanivannan<sup>4</sup>,  
R. Thirumalai<sup>1</sup> and K. Haripriya<sup>1</sup>**

<sup>1</sup>Student, SS Institute of Pharmacy, Sankari, Salem-637301.

<sup>2</sup>Assistant Professor, SS Institute of Pharmacy, Sankari, Salem-637301.

<sup>3</sup>Associate Professor, Annai College of Pharmacy, Nambipatti, Harur-636903.

<sup>4</sup>Professor & Principal, SS Institute of Pharmacy, Sankari, Salem-637301.

Article Received on  
28 March 2025,

Revised on 18 April 2025,  
Accepted on 08 May 2025

DOI: 10.20959/wjpr202510-36718



**\*Corresponding Author**

**K. Arunkumar**

Student, SS Institute of  
Pharmacy, Sankari, Salem-  
637301.

**ABSTRACT**

Herpes zoster, commonly known as shingles, is a viral infection caused by the reactivation of the varicella-zoster virus, the same virus responsible for chickenpox. It primarily affects older adults or individuals with weakened immune systems. The disease is characterized by a painful, blistering skin rash, often localized to a specific dermatome. This review focuses on the epidemiology, pathophysiology, clinical presentation, diagnosis, and treatment of herpes zoster. Additionally, the article discusses complications, such as postherpetic neuralgia, and the impact of vaccination in preventing the disease. Recent advancements in antiviral therapies and immune response modulation are also explored, providing a comprehensive overview of current strategies in managing and preventing shingles.

**KEYWORDS:** Herpes Zoster, Shingles, Treatment, Diagnosis, History, mechanism.

**INTRODUCTION**

Herpes zoster (Commonly referred to as “shingles”) and post-herpetic neuralgia result from reactivation of the varicella-zoster virus acquired during the primary varicella infection, or chickenpox. Whereas varicella is generally a disease of childhood, herpes zoster and post-herpetic neuralgia become more common with increasing age. Factors that decrease immune function, such as human immunodeficiency virus infection, chemotherapy, malignancies and chronic corticosteroid use, may also increase the risk of developing herpes zoster.

Reactivation of latent varicella-zoster virus from dorsal root ganglia is responsible for the classic dermatomal rash and pain that occur with herpes zoster. Unlike varicella (chickenpox), herpes zoster is a sporadic disease with an estimated lifetime incidence of 10 to 20 percent. The incidence of herpes zoster increases sharply with advancing age, roughly doubling in each decade past the age of 50 years. Herpes zoster is uncommon in persons less than 15 years old. In a recent study, patients more than 55 years of age accounted for more than 30 percent of herpes zoster cases despite representing only 8 percent of the study population. In this same study, children less than 14 years old represented only 5 percent of herpes zoster cases.<sup>[1]</sup>

Published data on the incidence of shingles ranges between 1.3 and 4.8 per 1000 cases annually. Few studies record age-standardized data and thus it is difficult to compare results. This study is concerned solely with possible gender differences. Liesegang, in a review of several epidemiological studies suggested there may be a slight excess incidence in females over males. The database now includes approximately 38,000 cases of shingles since 1967 and has been used extensively for epidemiological studies and for economic evaluation of the impact of shingles and of chickenpox.<sup>[2]</sup>

Furthermore, HZ complications are potentially life-threatening. HZ reactivation has been reported as a possible adverse event after COVID-19 vaccination. Treatment options and prevention by vaccination are of clinical importance. HZ can present with different clinical manifestations, some manifestations carry a higher risk of complications. The literature related to HZ continues to evolve, especially in regard to patients with comorbidities and immunocompromised patients. VZV reactivation has emerged as an important point of discussion during the COVID-19 pandemic, especially after vaccination.<sup>[3]</sup>

The annual death ratio specifically attributed to shingles or Herpes Zoster is relatively low compared to other infectious diseases. Most individuals with shingles recover without serious complications and mortality from shingles itself is rare.

## History

The history of shingles is quite fascinating. It's caused by the varicella-zoster virus, the same virus that causes chickenpox.

**Medical diagnosis:** Shingles was first isolated and characterized by Thomas Huckle Weller , Franklin Neva & Thomas C. Merigan in 1958.

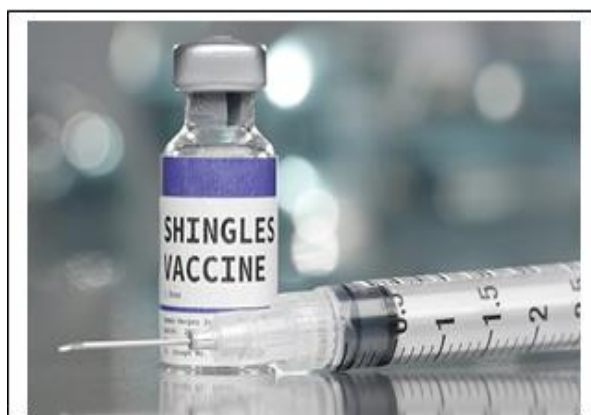**Meaning:** The term “HZ” originates from “Greek & Latin”. “Herpes” comes from the Greek word “Herpein” meaning “To creep” or “To crawl”, referring to the characteristic creeping or spreading nature of herpes virus infections. “Zoster” comes from the Greek word “Zoster” meaning “Girdle” or “Belt”. So “Herpes Zoster” essentially means “Belt-Like Creeping”.

**Ancient observations:** Historically, there are references to shingles-like symptoms dating back to ancient times, but the distinct link between chickenpox and shingles wasn't understood until much later.

**18th Century:** The term "shingles" was first used in the 18th century to describe the rash-like symptoms. However, it wasn't until the late 19th century that the connection between chickenpox and shingles was recognized.

**Viral discovery:** In the 20th century, advances in virology led to the identification of the varicella-zoster virus as the causative agent of both chickenpox and shingles. This discovery revolutionized our understanding of these conditions.

### Vaccine development

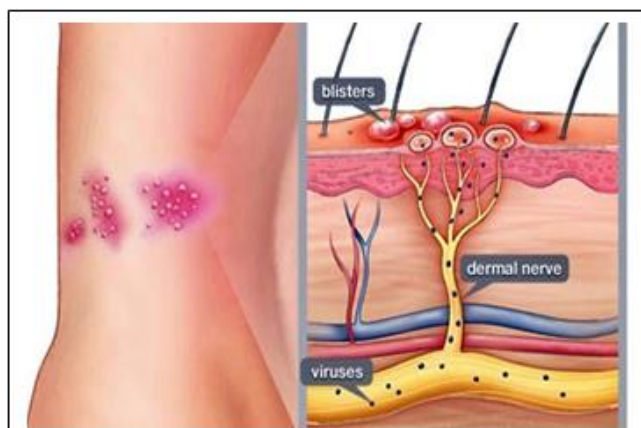


**Fig. 1**

The development of the varicella vaccine in the 20th century was a significant milestone in the prevention of both chickenpox and, indirectly, shingles. Subsequent to this, a separate vaccine specifically for shingles, called the herpes zoster vaccine, was developed and recommended for adults over a certain age.

**Ongoing research:** Research into shingles continues to explore various aspects, including the pathogenesis of the virus, risk factors for developing the condition, and potential treatments or preventive measures.

## Pathophysiology



**Fig. 2**

It is caused by Varicella-Zoster Virus, the same virus causes chicken pox. The first exposure to the virus, usually during childhood, leads to chickenpox. After the primary infection resolves, the virus moves to sensory ganglia of spinal and cranial nerves, where it becomes inactive. The body's immunity against chickenpox suppresses viral replication, keeping it dormant for decades. Reactivation of the virus occurs when this immunity weakens and fails to contain the virus. This can happen as a result of aging, stress or other diseases.<sup>[4]</sup>

### Reactivation occurs when immunity weakens

**Aging:** Risk increases significantly after age 60.

Stress, Immunocompromised, AIDS, Cancers.

Instead of another case of chickenpox, the reactivated virus causes shingles. It multiplies and spreads along the path of the infected nerve resulting in damage and pain at the location of pain. Depends on the nerve that is affected. Because each spinal nerve supplies a specific area of the body, called dermatome, the patterns of pain follow the dermatome distribution. When a cranial nerve is infected, face pain result. As the affected nerves transmit signals, pain results. As nerves come in pairs and usually only one is affected, the pain is typically limited to the small area on one side of the body.

### The phase of infection

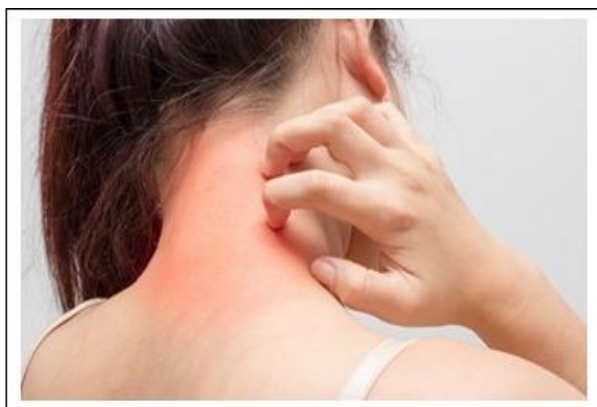Shingles develops in 3 phase.

#### Phase 1:

Pain only, 1 to 4 days (up to 10 days)

Stabbing pain, Burning, Numbness, Tingling. Patients typically experience pain as the first symptom. The pain can be described as a stabbing pain, or a burning, numbness or tingling sensation. The area is sensitive to touch. Depending on the location, the pain can sometimes be mistaken for a lung, heart or kidney problem. Less common symptoms include. Fatigue, headache and fever.

### Phase 2



**Fig. 3**

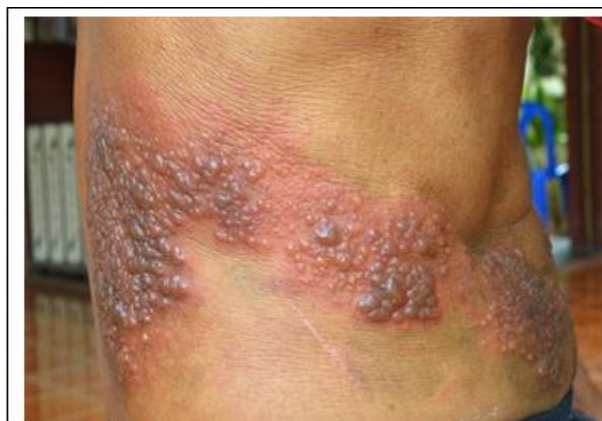Painful skin rash, 7-10 days. A painful skin rash appears in phase 2, a few days after the pain. The rash starts as small red dots. Which develop into fluid-filled blisters. As the blisters follow the nerve path, they form a stripe on one side of the body. The blisters eventually dry out and crust over.

### Phase 3

Rash Healing 2 to 4 week's pain may persist. The healing occurs in phase 3, which may take several weeks. There's no cure for shingles, but it is usually self-limited and resolves on its own.

### Diagnosis

Generally, the diagnosis becomes clear when a skin eruption occurs, characterized by clustered vesicles on a red base. Key features include the location of redness, vesicles, crusting, and the patient's history of segmental pain. In the prodromal phase, diagnosing herpes zoster can be challenging, as patients typically report varying pain and tenderness that may mimic other conditions.



**Fig. 4**

**Standard laboratory tests are usually ineffective for diagnosing acute herpes zoster**

- In the erythematous phase, VZV serology (Like complement fixation) is not useful, though VZV IgG and IgM levels can provide some insight. PCR may help detect viral DNA in tissue.
- During the blister phase, the virus can be isolated from vesicle fluid and identified histopathologically in infected epidermal cells. PCR can also detect the virus in blisters and potentially in the erythema. The histopathological findings are distinctive, showing focal intercellular edema, ballooning degeneration, multinucleate giant cells, and intranuclear eosinophilic inclusion bodies.
- After the herpes zoster lesions have healed, serological tests can sometimes help confirm a past infection, using methods like the complement fixation test, immunofluorescence assay for VZV membrane antigens, or ELISA. However, isolating the virus from tissue is not possible post-healing. Chronic pain from postherpetic neuralgia can be diagnosed if there's a history of herpes zoster. Current technical and serological methods are inadequate, making clinical examination of skin eruptions essential for early diagnosis and antiviral treatment, particularly since differentiating herpes zoster from conditions like contact dermatitis, insect bites, or herpes simplex can be complex.<sup>[5]</sup>

**Laboratory test methods**

**Polymerase chain reaction (PCR)**

PCR is a highly sensitive technique for detecting VZV. It is effective in identifying VZV DNA in various specimens, including whole blood, serum, plasma, peripheral blood mononuclear cells (PBMC), saliva, and cerebrospinal fluid (CSF), making it valuable for the



early diagnosis of atypical herpes zoster in patients without a rash. In whole blood, approximately 60% of VZV is found in PBMCs and 40% in serum or plasma. Notably, the DNA positivity rate for VZV in PBMC samples detected by PCR is higher than that in plasma and serum samples among patients with herpes zoster. Additionally, in patients with central nervous system involvement, PCR analysis of CSF samples showed a higher VZV DNA positivity rate compared to plasma samples and serological detection methods.

Collecting saliva for VZV DNA detection is more convenient and accessible than plasma collection. In a study by Mehta et al., VZV DNA was successfully detected in the saliva of all 54 shingles patients (100%) on the day their rash first appeared.<sup>[5]</sup>

### **Antibody and Complement detection**

When VZV reactivates, serum VZV antibody levels remain elevated and significantly differ from those in healthy individuals. High serum antibody levels are closely linked to the development of shingles, making their measurement valuable for diagnosis. In a study using IgM antibody-capture radioimmunoassay (MACRIA) on 220 patients, 216 (98%) were confirmed to have shingles, with 94.4% of samples collected 2–6 weeks post-rash onset. Consequently, detecting VZV-IgM titers is particularly relevant within 3.5 weeks after symptom onset.

In a study of 141 patients with herpes zoster (HZ), the positive rates for VZV-IgG, VZV-IgM, and complement fixation (CF) tests were 93.9%, 12.0%, and 64.2%, respectively. Notably, VZV-IgG levels showed a strong correlation with CF titers, suggesting that CF titers are a good indicator of IgG levels. Additionally, CF titers tend to rise gradually over time and exhibit a weak correlation with the timing of symptom onset.<sup>[5]</sup>

### **Inflammatory cytokines**

VZV is associated with the dorsal root ganglia, leading to inflammation of the nerve roots and alterations in cytokine levels throughout the body. Galectin-3, a member of the beta-galactoside-binding lectin family, is secreted by monocytes, phagocytes, and epithelial cells. It plays a role in various biological processes, including cell interactions, regulation of the cell cycle, growth control, mRNA precursor splicing, and angiogenesis. Following VZV infection, there was a notable increase in both mRNA and protein levels of galectin-3 in the spinal cord's dorsal horn of mice. When galectin-3 was deleted in mice or an antibody against galectin-3 was injected intrathecally, there was a significant reduction in tactile pain,

indicating that galectin-3 is implicated in the development of postherpetic neuralgia (PHN). Additionally, studies have shown that plasma levels of galectin-3 and IL-6 in patients with herpes zoster (HZ) neuralgia were significantly elevated compared to those in healthy individuals. This suggests that galectin-3 may serve as a potential biochemical marker for patients at risk of developing pre-HZ and PHN.<sup>[5]</sup>

### **Proteomic Analysis and Non-coding RNA**

Wang et al. identified 44 differentially expressed proteins in the plasma of herpes zoster (HZ) patients. These proteins were primarily involved in pathways such as the MAPK signaling pathway, neuroactive ligand-receptor interactions, acute myeloid leukemia, and transcriptional regulation disorders in tumors. From these, six key molecules were chosen for further investigation. Plasma samples from 40 HZ patients and 40 healthy controls were analyzed using ELISA, immunoblot assays, and receiver operating characteristic curve analysis. Ultimately, three proteins—PLG, F2, and VTN—were identified as potential biomarkers for early detection of HZ.

VZV-encoded small noncoding RNAs (sncRNAs) play a role in productive infections in neurons and fibroblasts, with at least one VZV sncRNA identified as capable of reducing viral replication. Given that sncRNAs are seen as potential targets for antiviral therapy, recognizing these molecules in VZV could open new avenues for developing treatments for herpes zoster (HZ) pain.<sup>[5]</sup>

### **Non-invasive examination**

#### **Infrared thermal imaging**

Infrared imaging technology employs thermal infrared wavelengths from 2 to 1000  $\mu\text{m}$  to capture images of objects using materials sensitive to infrared signals. This technique is widely used in clinical research. It gathers infrared radiation emitted by the human body and transforms it into digital signals, producing pseudo-color heat maps that accurately represent temperature differences in various regions.

The technology offers numerous benefits, including being non-invasive, free from radiation, easy to use, fast, and cost-effective. Infrared thermography is useful for identifying degenerative necrosis and vasoconstriction in local tissues, often appearing as varying levels of local hypothermia. In contrast, conditions with high metabolic activity, such as granulation



tissue growth, aseptic inflammation, edema, vasodilation, or tumor invasion, may present as increased local temperatures.

The skin area impacted by patients with herpes zoster (HZ) shows signs of inflammation. That infrared thermography is more effective than visual analog scale scoring for the early diagnosis of HZ neuralgia prior to the rash appearing. This method is advantageous due to its simplicity, non-invasive nature, and lack of radiation.<sup>[6]</sup>

### **High-Frequency ultrasound diagnosis**

High-frequency ultrasound diagnosis is a non-invasive approach that allows for the examination of the epidermis, dermis, subcutaneous tissue, and skin nerve structures. It correlates well with histopathology and is extensively utilized for diagnosing benign skin tumors, malignant tumors, localized scleroderma, and other conditions. In shingles patients, the primary pathological changes involve inflammation in the affected skin, subcutaneous tissues, nerve roots, and nerve endings.

On the affected side, the skin and subcutaneous tissue were notably thicker than on the healthy side, with a significant thickening of the cutaneous nerve linked to demyelinating lesions and edema of the nerve roots. Patients typically experience neuralgia prior to the eruption, and the affected nerve roots start showing pathological changes like demyelination or edema. Therefore, high-frequency ultrasound images should be clinically monitored in cases of pre-eruption neuralgia.

Unfortunately, research on this subject is limited. However, advancements in neuro ultrasound are likely to enhance the diagnosis of pre herpetic HZ neuralgia using high-frequency ultrasound.<sup>[6]</sup>

### **Treatment**

The primary goals of treating herpes zoster are to reduce pain, promote rapid healing, and prevent complications. Antiviral therapy is initiated immediately upon diagnosis, helping to lower the risk of post-herpetic neuralgia. Corticosteroids can be beneficial for managing pain and skin eruptions.

Additional treatment measures include isolating the patient to prevent nosocomial infections and providing localized care for skin lesions. Patient isolation is essential to minimize the risk of spreading infections.<sup>[7]</sup>

**Antiviral agent**

Antiviral medications like acyclovir, famciclovir, and valacyclovir have demonstrated effectiveness in alleviating acute herpes zoster (HZ) pain, accelerating lesion recovery, and preventing postherpetic neuralgia (PHN). Clinical trials indicate that antiviral agents are among the most crucial treatments for HZ. Given their favorable risk-benefit profile and good tolerance, healthcare providers should prescribe these medications to HZ patients as early as possible. Clinical trial findings suggest that antiviral treatment should begin within 72 hours of the onset of the rash.<sup>[8]</sup>

Antiviral agents can be divided into two categories based on their dependence on viral phosphorylation for activation. Acyclovir, famciclovir, and valacyclovir are nucleoside analogs that are converted into active triphosphate forms, which inhibit viral DNA polymerase and reduce the replication of human herpes viruses. Generally, patient adherence to valacyclovir and famciclovir is notably better than with acyclovir, as valacyclovir and famciclovir offer higher bioavailability. This results in less frequent dosing compared to acyclovir.<sup>[8]</sup>

The combination of acyclovir and ultraviolet B (UVB) treatment has been found to lower the incidence of subacute herpetic neuralgia (41.67%) and postherpetic neuralgia (PHN) (16.67%) compared to patients receiving acyclovir alone (61.54% and 46.15%, respectively). Adverse effects, including erythema and first-degree burns, were observed in patients undergoing UVB therapy. However, patients recovered after adjusting the dosage.<sup>[7]</sup>

Oral acyclovir taken within 72 hours of rash onset can reduce the incidence and severity of herpes zoster ophthalmicus, though a study by Aylward. found it ineffective against ocular complications, likely due to delayed treatment. Topical acyclovir offers no prophylactic benefits. Combining 830 nm LED therapy with famciclovir improves wound healing and pain relief. Early antiviral treatment is crucial to prevent visual impairment and blindness. A survey revealed that 56% of cornea specialists preferred acyclovir prophylaxis, while 63% favored oral antivirals with topical steroids for recurrent cases. Ganciclovir gel is effective for persistent pseudodendritic lesions. For acute retinal necrosis/PORN syndrome, a regimen of intravenous acyclovir followed by oral acyclovir is recommended.<sup>[7]</sup>

### Systemic corticosteroids

Corticosteroid therapy is advised for conditions such as acute zoster pain, Ramsay Hunt syndrome, and ocular complications, particularly when used alongside antiviral agents. Early intervention with acyclovir and steroids has yielded notable benefits in both adults and children with Ramsay Hunt syndrome, improving hearing recovery and facial nerve function. Common treatment regimens involve acyclovir (250 mg IV or 800 mg orally) combined with prednisone (1 mg/kg/day) for varying durations. For patients over 50, this combination has enhanced quality of life and aided rash resolution, although the long-term impact on postherpetic neuralgia prevention remains uncertain. Research on the effectiveness of corticosteroids in preventing postherpetic neuralgia has produced mixed findings. In cases of granulomatous arteritis, intravenous acyclovir and high-dose prednisolone are recommended, though there is a risk of irreversible cerebral infarction. Ultimately, the effectiveness of corticosteroids in managing herpes zoster is still unclear.<sup>[7]</sup>

### Acyclovir resistant herpes zoster

Acyclovir resistance is frequently seen in severely immunocompromised patients undergoing long-term acyclovir treatment for varicella zoster virus and herpes zoster virus infections. This resistance typically arises from mutations in the viral thymidine kinase, which diminish its enzymatic function. A study from Turkey highlighted that early detection of resistance, along with the use of foscarnet and cidofovir, can help reduce mortality in immunocompromised individuals. The recommended dosage of foscarnet for acyclovir-resistant varicella zoster virus infection is 120 mg/kg/day (either 40 mg/kg three times daily or 60 mg/kg twice daily). In their research, Breton et al. used a higher foscarnet dose of 200 mg/kg/day for acyclovir-resistant herpes zoster, with 10 of 13 patients showing positive responses.<sup>[7]</sup>

Additionally, mutations in viral DNA polymerase can lead to an inability to recognize acyclovir triphosphate, resulting in cross-resistance to foscarnet. Blot et al. found that cidofovir serves as a salvage therapy for patients with severe herpes simplex virus infections resistant to both acyclovir and foscarnet. Cidofovir, a monophosphate nucleotide analogue, is converted to its active form, cidofovir diphosphate, independently of viral mechanisms, making it resistant to mutations affecting phosphorylase activity. Ross recommended combined therapy with intralesional interferon alfa-2b and 1% trifluorothymidine ophthalmic

solution as a third-line option for acyclovir-resistant herpes zoster when other treatments are ineffective.<sup>[7]</sup>

### **Treatment of herpes zoster in pregnancy**

Acyclovir or valacyclovir can be utilized to treat herpes zoster during pregnancy, with acyclovir being the preferred medication in early pregnancy, as it does not increase the risk of malformations or preterm births. For example, a 28-week primigravida who received acyclovir along with acetaminophen for herpes zoster neuralgia had a positive response and subsequently delivered a healthy baby two months later. Similarly, a 17-week pregnant woman treated with valacyclovir for herpes zoster also had a favorable outcome.<sup>[7]</sup>

According to the recommendations from the Centers for Disease Control and Prevention (CDC) Advisory Committee on Immunization Practices (ACIP), varicella zoster immune globulin is highly recommended for susceptible pregnant women exposed to varicella, as it helps prevent complications during pregnancy, and for immunocompromised children after significant exposure. Neonates born to mothers who had varicella or herpes zoster within five days before and two days after delivery should receive varicella zoster immune globulin, regardless of whether the mother previously received the globulin. However, healthy neonates whose mothers had varicella more than five days before delivery do not need the immune globulin, as they are already protected by maternal antibodies transferred through the placenta. Furthermore, premature infants exposed postnatally to varicella or herpes zoster should be administered varicella zoster immune globulin due to their compromised immune systems and lower likelihood of acquiring maternal antibodies.<sup>[7]</sup>

### **Treatment of herpes zoster in children**

Herpes zoster is uncommon in children, and when it does occur, it is typically benign. However, if a child develops new lesions beyond three weeks after infection, underlying immunodeficiency should be investigated. While an oral suspension of acyclovir can be administered to children, it is not routinely prescribed for preadolescents, as it is not approved for that age group. Acyclovir treatment is advised for preadolescent children if they exhibit ocular involvement, have compromised immune systems, or are undergoing treatment for malignancies. In the absence of these factors, no specific treatment is generally given.<sup>[7]</sup>

Four infants aged 4 to 11 months with infantile herpes zoster were treated with either oral (three cases) or IV (one case) acyclovir and all recovered fully without complications; all had

a history of exposure to the varicella zoster virus. Zoster in infants and neonates typically results from transplacental transmission during maternal varicella zoster virus infection during pregnancy. Children can develop herpes zoster in the first decade of life due to varicella zoster virus infection before two months of age, and similarly, those in their first two decades may experience zoster if infected with the virus before 12 months. According to CDC ACIP guidelines, the varicella zoster vaccine is recommended only for children aged 1 year and older and is not indicated for preventing zoster. Furthermore, the CDC ACIP does not recommend the herpes zoster vaccine for anyone under 60 years of age. There is no vaccine recommendation for children to prevent zoster infection after exposure to varicella in their first year of life. Neonatal herpes zoster is very rare, with an estimated incidence of 0.74 cases per year, and if it does occur, it is usually left untreated due to its benign nature in preadolescents unless a severe infection or ocular involvement is present.<sup>[7]</sup>

### **Treatment of herpes zoster in immunocompromised individuals**

Acyclovir is effective for preventing herpes zoster in immunocompromised patients. A study in Africa showed that prophylactic acyclovir (400 mg twice daily) reduced the incidence of herpes zoster by 62% in HIV-infected individuals with CD4+ T cell counts over 250 cells/ $\mu$ L. Topical acyclovir, applied four times daily for 10 days, effectively treats localized herpes zoster and can reduce hospitalization and IV side effects.<sup>[7]</sup>

Oral brivudin is as effective as IV acyclovir for patients with malignancies, using a 5-day regimen of 125 mg every 6 hours. Valacyclovir, at 1-2 g three times daily, is a cost-effective outpatient option compared to inpatient IV acyclovir. A study by Trying found famciclovir to be well tolerated as an alternative to acyclovir. An HIV patient initially unresponsive to valacyclovir later improved with IV acyclovir. More extensive clinical trials are needed to assess valacyclovir's efficacy. Acyclovir is also used prophylactically in patients receiving bortezomib for multiple myeloma.<sup>[7]</sup>

### **Pharmacologic treatment**

#### **Antidepressants**

Tricyclic antidepressants (TCAs), including amitriptyline, nortriptyline, and desipramine, are effective in alleviating chronic pain associated with postherpetic neuralgia (PHN) when standard pain relief methods are inadequate. These medications function by blocking the reuptake of serotonin and norepinephrine and inhibiting sodium channels, with a number needed to treat (NNT) ranging from 2.1 to 2.6.<sup>[8]</sup>

However, TCAs can lead to various anticholinergic side effects, such as dry mouth, constipation, and blurred vision, as well as serious cardiac complications like QT prolongation. Therefore, it is important for healthcare providers to review baseline electrocardiograms before initiating treatment, particularly in elderly patients or those with heart issues. Treatment should start with a low dose of 10 mg at bedtime, gradually increasing to a target of 50-100 mg per day. Nortriptyline and desipramine tend to be better tolerated than amitriptyline and should be considered for older adults.<sup>[8]</sup>

### **Anticonvulsants**

A variety of anticonvulsants have been explored for managing neuropathic pain conditions, including trigeminal neuralgia and postherpetic neuralgia (PHN). Second-generation anticonvulsants like pregabalin and gabapentin are generally considered safe and well tolerated, in contrast to first-generation drugs such as carbamazepine and valproic acid. While their precise analgesic mechanisms are not fully understood, both pregabalin and gabapentin act on the same receptor.<sup>[8]</sup>

### **Opioids**

The use of opioids for neuropathic pain management, including postherpetic neuralgia (PHN), has gained support from recent studies showing their effectiveness. A 2002 crossover randomized controlled trial demonstrated that opioids provided a 38.2% pain relief rate compared to 31.9% for tricyclic antidepressants (TCAs) and 11.2% for placebo, with NNTs of 2.8 for opioids and 3.7 for TCAs.

However, opioid therapy is associated with side effects like nausea, itching, dizziness, sedation, and persistent constipation. To address this, constipation prophylaxis should be considered when prescribing opioids.<sup>[8]</sup>

### **Tramadol**

Tramadol, a synthetic analogue of codeine, functions as a  $\mu$ -opioid receptor agonist while also inhibiting the reuptake of serotonin and norepinephrine, effectively combining the characteristics of an opioid and a tricyclic antidepressant (TCA). A randomized controlled trial from 2003 showed that tramadol significantly enhanced quality of life and reduced pain in patients with postherpetic neuralgia (PHN), achieving a number needed to treat (NNT) of 4.8. However, tramadol is associated with side effects, including nausea, dizziness, constipation, drowsiness, and headaches. Care should be taken when using tramadol in



conjunction with selective serotonin reuptake inhibitors or monoamine oxidase inhibitors, as this combination may raise the risk of serotonin syndrome or seizures.<sup>[8]</sup>

### Topical lidocaine

The 5% lidocaine patch offers localized analgesia to the affected area without inducing complete anesthesia. It also protects the skin from mechanical irritation. Clinical trials have shown that the lidocaine patch significantly reduces pain and allodynia in patients with postherpetic neuralgia (PHN). Because topical lidocaine has minimal systemic absorption, it boasts a favorable safety and tolerability profile. Some patients may experience mild to moderate localized skin reactions. Pain relief can be noticeable within two to three weeks of starting treatment, and the patch may provide long-term relief for those with PHN.<sup>[8]</sup>

### CONCLUSION

Shingles, or Herpes Zoster, is a significant public health concern due to its prevalence and potential for severe complications, especially in the elderly and immunocompromised individuals. Caused by the reactivation of the varicella-zoster virus, it presents with painful, unilateral rashes and can lead to long-term consequences like postherpetic neuralgia. The advent of vaccines, such as the recombinant zoster vaccine, has proven to be a game changer in reducing the incidence and severity of the disease. Early diagnosis and antiviral treatment are crucial in managing symptoms and preventing complications. However, continued research and public health efforts are needed to enhance vaccine accessibility and awareness, especially in at-risk populations. The evolving understanding of Herpes Zoster underscores the importance of preventive strategies and timely medical interventions to mitigate its impact on individuals and healthcare systems.

This study identified several risk factors for developing herpes zoster (HZ) infection. Many of these factors are already recognized by both patients and clinicians, which can help inform discussions about preventive measures, including vaccination.

Increased and improved herpes zoster education is clearly needed in the respected curriculums for students in the health professions, and in the continuing education for health professionals.

There needs to be more awareness among people about herpes zoster. Even in rural areas, the treatment of this is largely unknown.

**REFERENCE**

1. D.M Fleming et.al, Gender difference in the incidence of Shingles, Cambridge Journal, doi.org/10.1017/S0950268803001523, 2004; 132: 1.
2. Seth John Stankus et.al, Management of Herpes Zoster (Shingles) and postherpetic Neuralgia, American Academy of Family Physicians, april, 2000.
3. Uwe Wollina, Herpes Zoster: A review of clinical manifestation and management, Viruses journal, 2022; 14. doi-10.3390/v14020192
4. Jeffrey M.weinberg MD, Herpes Zoster: Epidemiology, Natural history and common complications, Journal of the American Academy of Dermatology, doi-10.1016/j.jaad.2007.08.046, 2007; 57.
5. Manfred H. Wolf, S. Schunemann, A. Schmidt, Varicella-Zoster Virus: Molecular biology, pathogenesis and clinical aspects.
6. Yong Fei, Early Diagnosis of Herpes Zoster Neuralgia: A Narrative review, Pain and therapy, doi:10.1007/s40122-023-00510-4, 2023; 12.
7. Elsam Koshy et.al, Epidemiology treatment and prevention of herpes zoster, Indian journal of Dermatology, venereology and leprology, doi-10.4103/ijdv.IJDVL-1021-16, 2018.
8. Young Hoon Jeon, Herpes zoster and postherpetic neuralgia: Practical consideration for prevention and treatment, The korean journal of pain, doi-10.3344/kjp.2015.28.3.177, 2015; 28.