

EFFECT OF INDIGENOUS ANTHELMINTIC *CARICA PAPAYA* AGAINST GASTROINTESTINAL NEMATODES IN CATTLE

Bhoopendra Kumar*, Y.P. Sahni, Nitesh Kumar

Department of Veterinary Pharmacology and Toxicology, College of Veterinary Science and
AH, Jabalpur - (M.P.)

Article Received on
24 Sept 2014,

Revised on 19 Oct 2014,
Accepted on 13 Nov 2014

***Correspondence for
Author**

Dr.Bhoopendra Kumar

Department of Veterinary
Pharmacology and Toxicology,
College of Veterinary Science
and AH, Jabalpur - (M.P.)

ABSTRACT

The anthelmintic efficacy of *Carica papaya* was elaborated against gastrointestinal nematode and effect on haemato-biochemical parameter in cattle. Cattle were treated with *Carica papaya* cold aqueous extract 500mg/kg body weight for 10 days. Haemato-biochemical parameters Hb, TEC, TLC, PCV, ESR, DLC, Total serum protein, serum albumin, SGOT, lactate dehydrogenase (LDH) and serum glucose measured at the beginning and 10th day of post treatment. The mean egg per gram of faeces (EPG) was done on day 1st (Pre-treatment) and day 10th, 20th, 30th day of post treatment. Cattle treated with cold aqueous extract *Carica papaya* exhibited effect on haemato-biochemical parameters, increase in Hb, TEC, PCV,

Monocytes lymphocytes, total serum protein, serum albumin and serum glucose however, TLC, ESR eosinophils, SGOT and serum lactate dehydrogenase (LDH) was significantly decreased. Cold aqueous extract *Butea frondosa* exhibited a gradual decrease in EPG of parasites; *Trichostrongyles*, *Toxocara*, *Oesophagostomum* and *Trichuris spp.* on day 10, 20 and 30 post treatments. The maximum anthelmintic efficacy was found against *Trichuris spp.* 94.4 percent on post day of treatment. The anthelmintic efficacy against *Oesophagostomum spp.*, *Trichostrongylus spp* and *Toxocara spp.* was exhibits 86.8, 86.7 and 79.8 percent respectively. It can be concluded that cold aqueous extract of *Carica papaya* showed good anthelmintic efficacy so that it can be used as an alternate anthelmintic and will be cost effective.

KEYWORDS: Anthelmintic, *Carica papaya*.

INTRODUCTION

Endoparasitic infestation is one of the major problems in livestock animals which are clinically characterized by enteritis, diarrhoea, constipation, dysentery, anaemia, emaciation, dehydration and death^[1] (Ahmad *et al.*, 1990). A number of synthetic anthelmintic are available and used for the treatment of helminthiasis. The improper use of anthelmintic resulted in emergence of resistance in worms.

Medicinal plants are of great value in the treatment of parasitic infestation. Several modern researchers have elaborated the use of natural plants, being safer than synthetic chemicals. Modern allopathic drugs are often not available at the door of farmers or may be expensive to poor livestock raiser.

For these instances herbal anthelmintic offers a valuable alternative in the treatment of parasitic infestation in animals. *Carica papaya* commonly known as 'Papaya' belongs to family Caricaceae and its fruits, leaves latex and roots are used medicinally. The application of papaya latex and powdered air-dried seeds has been claimed as an anthelmintic.

MATERIALS AND METHODS

Collection and processing of herbal plant seeds

Seeds of *Carica papaya* were obtained from the Department of Aromatic and Medicinal Plants, College of Agriculture Science, Jawaharlal Nehru Krishi VishwaVidyalaya, Jabalpur. Seeds were crushed, powdered and sieved through muslin cloth. The aqueous extract of the seeds was prepared^[2] as per method given by Rosenthaler (1930).

Collection of faecal samples

Freshly laid or rectal faecal samples of each experimental animal were collected in an individually labelled polythene bag before and after treatment on the scheduled day.

Examination faecal for eggs of gastrointestinal nematodes

The assessment of status of parasitic infestation was made on the basis of faecal examination by qualitatively by modified sheather's sugar floatation technique^[3] (Sloss *et al.*, 1994) and quantitative techniques by modified McMaster egg-counting technique^[3] (Sloss *et al.*, 1994) for the eggs in naturally infected cattle. Faecal examination was done on day 0 (before treatment) and on day 10th day 20th and 30th (after treatment).

Calculation of Percent efficacy

Percent efficacy of anthelmintic activity of plants will be calculated by using the following formulae^[4] (Soulsby, 1982).

$$\% \text{ efficacy} = \frac{\text{Mean EPG zero days} - \text{Mean EPG after treatment}}{\text{Mean EPG after treatment}} \times 100$$

Determination of effect of *C. papaya* on Haemato-Biochemical profiles

The effect of aqueous of *C. papaya* was studied on various clinical parameters at zero day (pre-treatment) and 10, 20 and 30 day (post treatment), haematological and biochemical parameters at zero day (pre-treatment) and 10 day (post treatment).

Collection of blood sample

The blood samples were collected aseptically from jugular vein of cattle on 0 day and 10 day (control and experimental groups). Approximately 3 ml blood collected in heparinised vial and 3 ml blood collected for serum separation. The following haematological and biochemical parameters were studied^[5] as per method (Feldman et al., (2000). Haemoglobin concentration (Hb g/dl), Total erythrocyte count (TECx106/ μ l), Total leukocytes count (TLCx103), Packed cell volume (PCV %), Erythrocyte sedimentation rate (ESR) (mm/hr), Differential leukocyte count (DLC %) and the biochemical parameters were studied viz, Total serum protein (mg/dl), Serum albumin (mg/dl), Serum SGOT (IU/L), Serum lactate dehydrogenase (IU/L) and Serum glucose (g/dl).

Anthelmintic treatment in cattle

The powdered seeds and aqueous extract of seeds of *C. Papaya* were administered orally in animals @ 500mg/kg bwt continuously for 10 days.

Statistical analysis

The data were analysed by Students't'- test as per the method^[6] (Snedecor and Cochran, 1994).

RESULT

Parasitic infected animals were treated with crude powder of *C. Papaya* (500 mg/kg, orally, daily for 10 consecutive days). The animals showed an improvement in general health condition along with increased appetite. CNS activity was improved. Colour and consistency of faeces observed to be normal after treatment. Animals responded effectively to pedal,

palpebral, touch, swallowing reflexes and recovered from anaemic condition. The body temperature of animal improved from 100.6 ± 0.05 to 101.8 ± 0.02 °F.

Table-1:- Clinical profile in Cattle treated with powder and cold aq. ext. of *C. papaya* (500 mg/kg orally, daily for 10 days daily)

S. No.	Clinical parameters	Pre treatment	Post treatment			
		Day 0	Day 5	Day 10	Day 20	Day 30
1.	CNS activity	++	++	+++	+++	++++
2.	Body reflexes	++	++	+++	++++	++++
4.	Clinical symptoms	Anaemic, Isolated	Pale M.M	Recovered	Recovered	Recovered
5.	Behavioural changes	Severe dullness	Dullness	Improve	Improve	Normal
6.	Body temp. (0F)	100.6 ± 0.05	101.2 ± 0.08	101.2 ± 0.06	101.7 ± 0.04	101.8 ± 0.02
7.	Effect on secretions	Dry muzzle	Moist muzzle	Moist muzzle	Moist muzzle	Moist muzzle
8.	Faecal colour and consistency	Diarrhoeic dark green	Diarrhoeic greenish	Normal semisolid	Normal	Normal
9.	Excretion of urine	Dark Yellowish	Yellowish	Normal	Normal	Normal

Haematological observations in cattle treated with cold aqueous extract of *C. papaya*:

The effect of cold aq. ext. of *C. papaya* on different haematological parameters has been depicted in the Table-1. The data revealed significant ($p < 0.01$) rise in mean Hb, mean TEC, PCV, However the mean value of TLC, neutrophils and eosinophils was significantly ($p < 0.05$) decreased.

Table-2:- Effect of aqueous extract of *C. papaya* (500 mg/kg, orally, daily for 10 days) on haematological parameters in cattle

Parameters	Pre treatment (day zero)	Post treatment (day 10)
Haemoglobin (g/dl)	7.77 ± 0.14	$9.20 \pm 0.11^{**}$
Total erythrocyte count (x106)	6.11 ± 0.21	$8.10 \pm 0.08^{**}$
Total leukocyte count (x103)	12.77 ± 0.45	$9.17 \pm 0.57^{*}$
Packed cell volume (%)	25.52 ± 0.26	$34.48 \pm 0.35^{**}$
Erythrocyte sedimentation (mm/hr)	0.92 ± 0.24	$0.27 \pm 0.11^{*}$
Differential leukocyte (%)		
Lymphocyte	49.30 ± 0.41	$62.5 \pm 0.57^{**}$
Monocyte	2.67 ± 0.33	$3.67 \pm 0.33^{*}$
Neutrophil	29.67 ± 0.52	$27.83 \pm 0.61^{*}$
Eosinophil	18.50 ± 0.43	$6.00 \pm 0.37^{**}$

*Significant $P < 0.05$

** Significant $P < 0.01$

Biochemical observations in cattle treated with cold aqueous extract of *C. papaya*:

The effect of cold aq. ext. of *C. papaya* on different biochemical parameters has been shown in the Table-2. The data showed significant ($p < 0.01$) increase in total serum protein mean value, mean serum albumin and serum glucose also whoever, The mean values of SGOT and LDH were highly significantly ($p < 0.01$) decreased.

Table-3:- Effect of aqueous extract of *C. papaya* (500 mg/kg, orally, daily for 10 consecutive days) on biochemical parameters in cattle

Parameters	Pre treatment (day zero)	Post treatment (day 10)
Total serum protein (g/dl)	6.04 \pm 0.14	7.74 \pm 0.07**
Serum albumin	2.04 \pm 0.06	3.38 \pm 0.06**
SGOT (IU/L)	138.02 \pm 0.65	84.87 \pm 0.41**
Lactate dehydrogenase (IU/L)	2355.67 \pm 2.45	998.27 \pm 2.09**
Serum glucose (g/dl)	38.48 \pm 0.44	46.22 \pm 0.62**

*Significant $P < 0.05$

** Significant $P < 0.01$

Effect of *C. papaya* (cold aqueous extract) on mean EPG of parasites

Cattle treated with cold aq. ext. of *C. papaya*, the mean EPG of *Trichostrongyles spp.*, *Toxocara spp.*, *Oesophagostomum spp.* and *Trichuris spp.* was significantly ($p < 0.01$) reduced (Table-3). The mean *Trichuris spp.* EPG was reduced from 2216.7 \pm 60.1 to 83.3 \pm 16.7 on day 30 after treatment which was found to be highly significant. The percent efficacy was calculated to be 96.2 percent on day 30. Similarly, EPG of *Oesophagostomum spp.*, *Trichostrongyles spp.* and *Toxocara spp.* was declined 84.4, 82.2 and 83.0 percent on day 30.

Table-4:-Mean EPG and percent anthelmintic efficacy of *C. papaya* (cold aqueous extract) against gastrointestinal nematodes in cattle

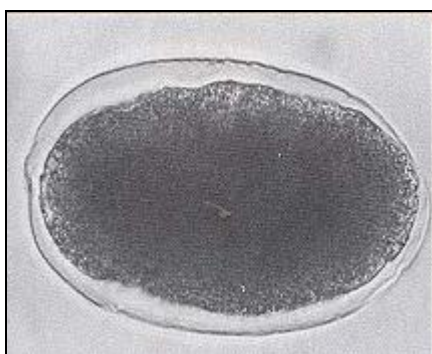
S. No.	Parasites	Pre treatment Zero day mean (EPG \pm SE)	Post treatment			Percent efficacy		
			10th day mean (EPG \pm SE)	20th day mean (EPG \pm SE)	30th day mean (EPG \pm SE)	Day 10th	Day 20th	Day 30th
1.	Trichostrongyles	2716.7 \pm 47.7	750 \pm 52.3**	616.7 \pm 36.5	566.7 \pm 21.1	72.4	77.3	82.2
2.	Toxocara	1866.7 \pm 49.4	516.7 \pm 30.7**	350 \pm 22.4	316.7 \pm 30.7	72.3	81.2	83.0
3.	Oesophagostomum	2666.7 \pm 49.4	550 \pm 22.4**	450 \pm 22.4	416.7 \pm 30.7	79.4	83.1	84.4
4.	Trichuris	2216.7 \pm 60.1	283.3 \pm 30.7**	183.3 \pm 30.7	83.3 \pm 16.7	91.2	94.3	96.2

*Significant $P < 0.05$

** Significant $P < 0.01$

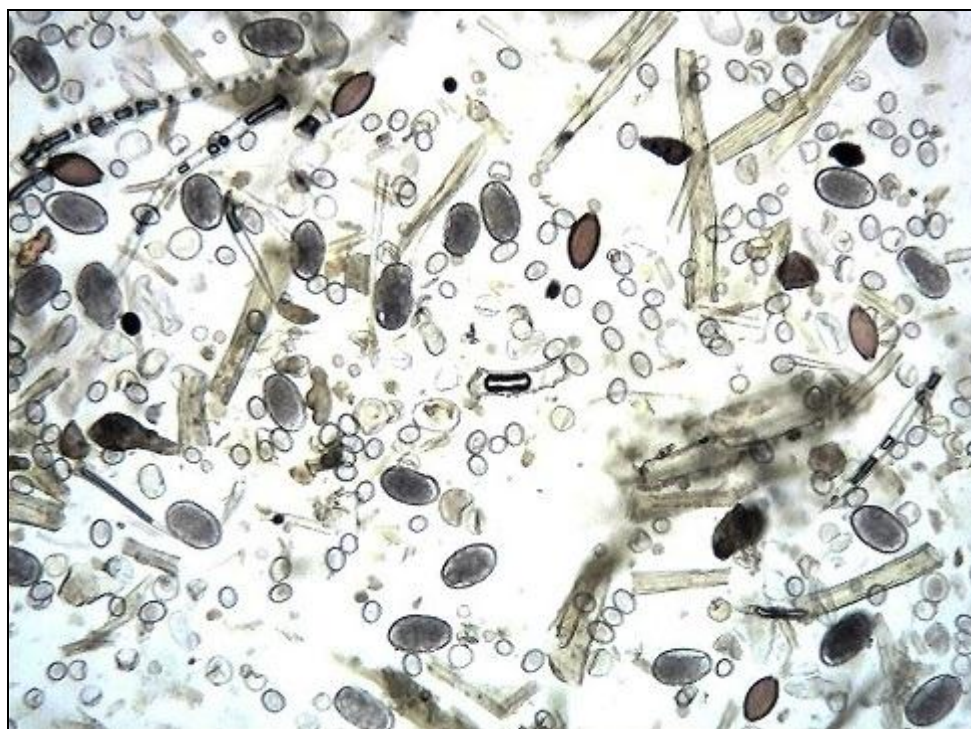

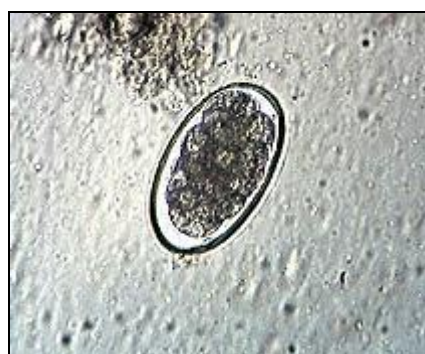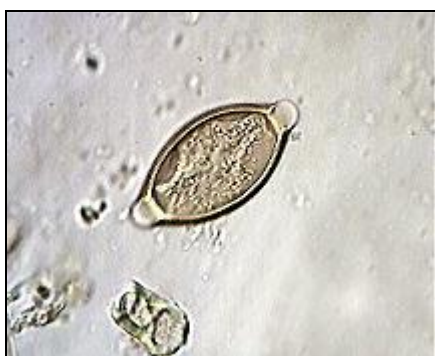Fig. 1 Egg of different parasites observed in faeces of Cattle. 100X



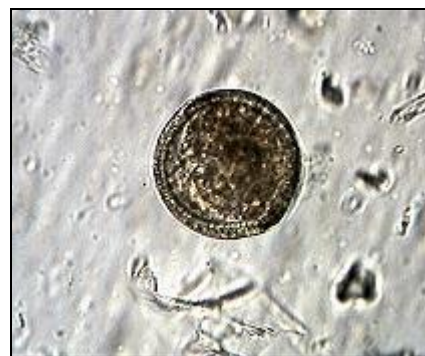Oesophagostomum spp.



Trichostrongyles spp.



Trichuris spp.



Toxocara spp.

Fig. 2 Egg of different parasites observed in faeces of Cattle. 400X

DISCUSSION

The observations recorded in this study clearly indicating that following treatment with *C. papaya*, there was a significant increase in haematological parameters such as Hb, TEC and PCV in cattle during the course of treatment. The present findings of increase in mean Hb concentration, TEC and PCV reported in present study^[7-12], Pal and Dasgupta, (2006); Padmaja *et al.* (2006); Das *et al.* (2005); Islam *et al.* (2005); Deshmukh *et al.* (2004) and Ramteke *et al.* (2004). The findings emanating from the present study indicate that the enhancement in level of Hb and TEC content of blood with *C. papaya* might be due to elimination of blood sucking gastrointestinal parasites and also due to increase in iron absorption from gastrointestinal tract. The significant increase in lymphocytes and monocytes after treatment was also recorded^[9] Islam *et al.* (2005). The immunosuppression is caused by heavy load of parasitic infestation in animals^[13]. However, haematological profile indicating an increase in lymphocyte and monocyte counts may be due to an immunostimulatory effect of indigenous extracts *C. papaya* exhibits potential immunomodulatory activity, significant enhancement of phytohaemagglutinin responsiveness of lymphocytes and also inhibit the complement mediated haemolytic pathway^[14] Mariluz *et al.* (2003). An increase in lymphocyte count following the administration of indigenous extracts, recorded in the present study^[14] Mariluz *et al.* (2003).

Biochemical study

The substantial burden of GIT nematode alters the biochemical parameters leading to hypoproteinemia, hypoalbumenia, decreased serum glucose level, increase SGOT and LDH in chronic parasitic infestation. The observations recorded in the present study clearly indicate that after treatment with *C. papaya*, there was a significant increase in biochemical parameters such as total serum protein, serum albumin and serum glucose levels. The increase in mean total serum protein, serum albumin and serum glucose levels reported in present study^[8,12,15-16] (Deshmukh *et al.*, 2004; Ramteke *et al.*, 2004; Rahman *et al.*, 2003; Waghmare *et al.*, 2000).

The findings emanating from the present study suggest that an enhancement in level of total serum protein, serum albumin and serum glucose level which could be due to removal of parasitic load from gastrointestinal tract. The endoparasitic infestation causes hypersecretion of mucous and protein leakage from gastrointestinal tract, which could be due to inflammation of intestinal epithelium^[11,17] (Padmaja *et al.*, 2006; Holmes, 1986). The

decrease in SGOT level recorded after treatment with *C. papaya*^[10] Pal and Dasgupta (2005). The findings indicated that increase of SGOT in parasitic infestation returned to normal after treatment which may be due to removal of worm load from gastrointestinal tract^[10] (Pal and Dasgupta, 2005). The increase in LDH level in parasitic infestation also returned to normal after anthelmintic treatment with *B. frondosa* and *C. papaya* is due to removal of parasitic burden from GI tract. Worm load causes decrease in feed intake, nutrient utilization and damage of GI tract, which leads to emaciation and reduction in body muscle mass^[18] (Symons, 1985).

Another indigenous plant, *C. papaya* was also employed in the present investigation to find out its anthelmintic efficacy against *Trichostrongyles*, *Toxocara*, *Oesophagostomum* and *Trichuris spp.* in cattle. The observations indicated anthelmintic efficacy *C. papaya* against *Trichuris spp.* to the extent of 96.2 percent which was found to be maximum among various spp. of parasites. The anthelmintic efficacy of *C. papaya* on other parasites viz: *Oesophagostomum* (84.4%), *Trichostrongyles* (83%) and *Toxocara* (82.2) were calculated in the present experiment.

Anthelmintic efficacy of *C. papaya* against other parasites such as *Strongyles spp.*, *A. suum*, *H. polygyrus* and *H. nana* has been reported by various research workers. The effectiveness of *C. papaya* seeds against *Strongyles spp.* of parasite in sheep^[19].

They further reported that oven dried seeds of *C. papaya* in the dose rate of 400 mg/kg b. wt. administered consecutive for 10 days, produced significant anthelmintic efficacy. The dose of *C. papaya* and duration of phytotherapy used in present study are in close agreement with findings of^[19] Hounzangbe et al. (2001). The anthelmintic efficacy of *C. Papaya* latex (4 g /kg b. wt.) against investigated *A. suum* on day 7 post treatment^[20] Satrija *et al.* (1994). The anthelmintic efficacy of *C. papaya* on gastrointestinal parasitism in chicken has been reported^[21] (Mpoame and Essomba, 2000), who found that aq. decoction of papaya seeds @ 5g /litre of water caused significant reduction in EPG count of *Heterakis spp.*, *Eimeria spp.* and *Capillaria spp.* of worms in poultry. However the available literature did not reveal any scientific data on anthelmintic efficacy of *C. Papaya* against *Trichostrongyles*, *Toxocara*, *Oesophagostomum* and *Trichuris spp.* of parasites in cattle.

CONCLUSION

The cold aqueous extract of *Carica papaya* showed good anthelmintic efficacy so that it can be used as an alternate anthelmintic and will be cost effective.

ACKNOWLEDGEMENT

I am thankful to all the authors who's helped me during my research.

REFERENCES

1. Ahmad MA, Mir AS, Pandir BA, Krimani MA. Clinical manifestation in sheep with parasitic infestation. *Journal of Veterinary Parasitology*, 1990; 4: 77
2. Rosenthaler L. The chemical investigation of plants. Publ., Bell and Sons, London; 1930; 36.
3. Sloss MW, Kemp RL, Zajac AM. *Veterinary Clinical Parasitology*. 6th edn. Publ., International Book Distributing Co., Lucknow, India; 1994. 191.
4. Soulsby E.J.L. *Helminths, Artropods and Protozoa of Domesticated Animals*. 7th edn. Publ., the English Language Book Society and Bailliere, Tindall, London; 1982; 261-270.
5. Feldman BF, Zinkl JK, Jain NC. *Schalm's Veterinary Haematology*. 5th edn., Publ., A. Walters Kluwer Company 2000; 1344-1348.
6. Snedecor GW, Cochran WA. *Statistical method*. 7th edn. Publ., Oxford and IBH Publishing Co. Calcutta; 1994; 445.
7. Das M, Prasad KD, Singh LB. Effect of gastrointestinal nematodiasis on the body weight and mortality in kids. *Journal of Veteterinary Parasitology*, 2005; 19(1): 73-74.
8. Deshmukh AA, Talokar SS, Vadlamudi VP. Haemato-Biochemical analysis of helminth-infested goats treated with a composite herbal extract. *In: Proc. Nat. Seminar on Herbal Remedies for Animal Health & Livestock Production*, Anjora, 22-24 December 2004. ISVPT, Anand.
9. Islam N, Agarwal MA, Islam MS, Sobhan MA, Rahman MM.. Efficacy of levamisole and triclabendazole against gastrointestinal nematode and trematode in crossbred cows. *Indian Journal of Veterinary Medicine*, 2005; 25(1): 24-27.
10. Pal S, Dasgupta CK. Haemato-biochemical profiles of buffalo in anthelmintic treatment against *fasciola gigantica* infection. *Buffalo Bulletin*, 2006; 25(2):40.
11. Padmaja BK, Kumar S, Haritha C. Haematology and blood biochemical profile of sheep with mixed endoparasitic infestation. *Indian Veteterinary Journal*, 2006; 83: 634-636.

12. Ramteke VD, Vadlamundi VP, Waghmare SP, Handa A, Maral UJ, Godse RA, Gaikwad SS. Clinical evaluation of indigenous herbal formulation against helminths infestation in sheep. *Indian Veterinary Medical Journal*, 2004; 24: 338 -340.
13. Suarez VH, Lorenzo R.M, Buseti MR, Santucho GM. Physiological and parasitological responses to nematode infections of fattening cattle in the Western Pampas of Argentina. *Vet Parasitology* 1999; 81(2):137-148.
14. Mariluz PMH, Angelica DF, Florecita DG, Xenia TT. Possible immunomodulatory actions of carica papaya seed extract. *Clin Hemorheol Microcirc*, 2003; 29(3-4): 219-29.
15. Rahman Zia-ur, Sandhu MA, Ahmad T. Haematological and serum biochemical profiles of buffalo heifers as influenced by levamisole. *Comparative Clinical Pathology*, 2003; 12(3): 147-150.
16. Waghmare SP, Rode AM, Sarode DB, Sapre VA. Efficacy of homeopathic drug 'Cina' against helminthiasis of buffalo calves with reference to haemobiochemical profile. *PKV Res J*, 2000; 24(1):59-60.
17. Holmes PH. Pathophysiology of nematode infection. In *Proceeding of the Sixth International Congress of parasitology*, (M. J. Howell, editor). Canberra: Australian Academy of Science, 1986.
18. Symons LEA, Jones WO. Skeletal muscle, liver and wool protein synthesis by sheep infected by the nematode *T. colubriformis*. *Australian J Agri Res*, 1975; 26:1063-1072.
19. Hounzangbe AMS, Zinsou FE, Affognon KJ, Koutinhoun BN, Diaye MA, Moutairou K. Antiparasitic Efficacy Of Papaya Seed Powder on Gastrointestinal Strongyles of Djallonke Sheep of Southern Benin. *Revue-d'Elevage-et-de-Medecine-Veterinaire-desPays-Tropicaux*, 2001; 54(3/4): 225-229.
20. Satrija F, Nansen P, Bjorn H, Murtini, He S. Effect of papaya latex against *Ascaris suum* in naturally infected pigs. *J. Helminth.*, 1994; 68(4): 343- 346.
21. Mpoame M, Essomba L. Treatment of gastrointestinal parasitoses of chickens with aqueous decoctions of papaya (*carica papaya*) seeds. *Revue-d'Elevage-et-de-Medecine-Veterinaire-des-Pays-Tropicaux*, 2000; 53(1): 23-25.