

BILATERAL COLOBOMA OF IRIS AND CHOROID WITH UNILATERAL MICROCORNEA AND ASTIGMATISM – A CASE REPORT

**Dr. Arun kumar S. Bilodi^{1*}, Dr. Muthu Ramalingam², Dr. Vijayalakshmi³, Dr. Vikas
Shantaram Kakade⁴ and Dr. P. Arunkumar⁵**

¹Professor and Head, Department of Anatomy, Velammal Medical College Hospital and
Research Institute, Madurai – 625009.

²Professor and Head, Department of Ophthalmology, Velammal Medical College Hospital
and Research Institute, Madurai – 625009.

³Assistant Professor, Department of Ophthalmology, Velammal Medical College Hospital
and Research Institute, Madurai – 625009.

⁴Senior Resident, Department of Ophthalmology, Velammal Medical College Hospital and
Research Institute, Madurai – 625009.

⁵Senior Resident, Department of Ophthalmology, Velammal Medical College Hospital and
Research Institute, Madurai – 625009.

Article Received on
28 Feb 2015,

Revised on 19 March 2015,
Accepted on 11 April 2015

***Correspondence for
Author**

**Dr. Arun kumar S.
Bilodi**

Professor and Head,
Department of Anatomy,
Velammal Medical
College Hospital and
Research Institute,
Madurai – 625009.

ABSTRACT

A 22 years old female came to outpatient department of ophthalmology at Velammal Medical College Hospital and Research Institute, Madurai with history of defective vision since birth. She had no systemic diseases. No family history of similar complaints. On examination she had bilateral coloboma of iris and choroid with microcornea in right eye. She was examined thoroughly and treated. Her vision improved on wearing glasses. Her vision improved on wearing glasses which is rare. Hence this case made us interesting to study in detail, and reported.

KEYWORDS: Defective vision, coloboma, microcornea, iris, choroid, astigmatism.

INTRODUCTION

Occurrence of ocular coloboma is due to incomplete closure of neuroectodermal optic cup that occurs between 5-8 weeks of intra uterine life.^[1] The coloboma affects the posterior segment of the eye which may be unilateral or bilateral. It occurs bilaterally in 60% of cases.^[2] The coloboma affects the retinal pigment epithelium (RPE),

neurosensory retina, or choroid due to failure of fetal fissure to close posteriorly.^[3]

<i>Legend-1 showing the coloboma of right eye</i>	<i>Legend-2 showing coloboma of right eye</i>
---	---

Chorioretinal coloboma may affect other systems like cardiovascular, nervous, musculoskeletal, gastrointestinal and genitourinary systems.^[4]

Incidences of coloboma

Studies have shown various incidences in different countries. They are

- 1) In Spain, it is 0. 5/10, 000 live births. ^[5]
- 2) In France it is 1. 4/10, 000 live births. ^[6, 7]
- 3) In United States it is 2. 6/10, 000 in the USA. ^[8]
- 4) In China, it is 7. 5/10, 000 live births. ^[9]
- 5) In Canada incidences of coloboma in blind adults ranges from 0. 6%-1. 9%. ^[10]
- 6) World wide incidences of coloboma in blind children ranges from 3. 2–11. 2% .^[11]

CASE REPORT

A 22 years old female from Madurai came to the outpatient department of ophthalmology with history of defective vision since birth. She had no systemic diseases. No similar complaints in her family.

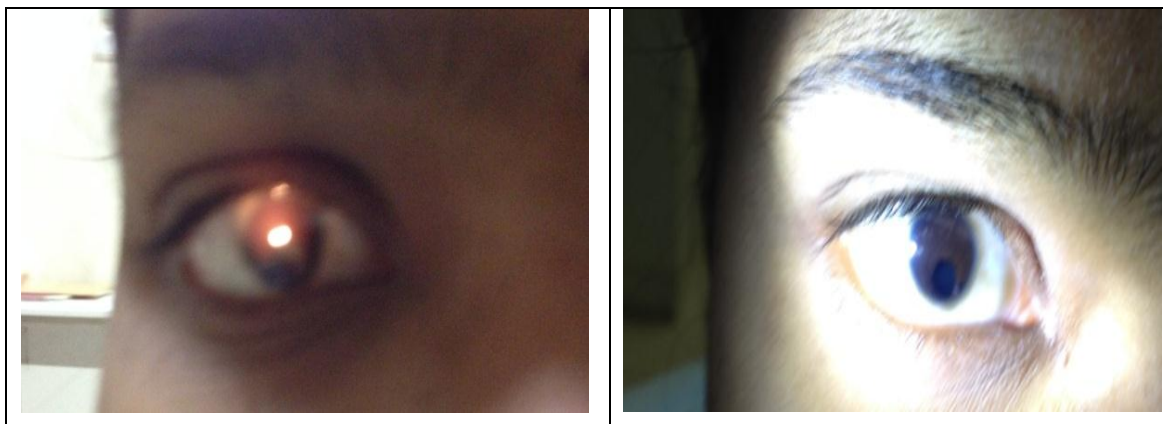
On general examination

She was underbuilt and moderately nourished. She had no cyanosis, jaundice, clubbing, and lymphadenopathy.

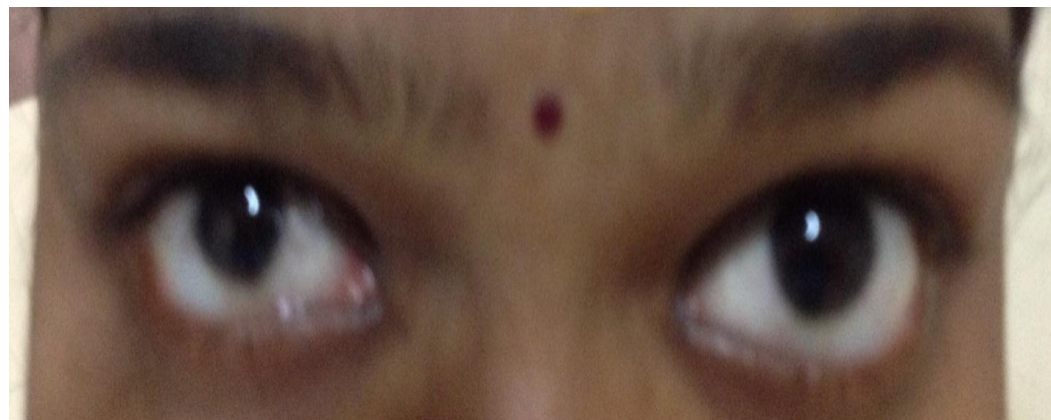On local examination

- 1) Microcornea of right eye
- 2) Bilateral coloboma of iris and choroid
- 3) Astigmatism in both eyes (right eye 3.0x15 degrees and in left eye -1. 0x180 degrees).

She was prescribed glasses to correct her astigmatism and refractory errors. Her vision improved to 6/9 after wearing the glasses which is of rare sequel. Optic discs were normal in both eyes.



Legend-3 showing microcornea of right eye and bilateral coloboma of iris



DISCUSSION

Chorioretinal colobomas are congenital anomalies present since birth.^[12] Vitamin A is very essential for development of eye.^[13] The retinal detachment is the most common complication that occurs in 8.1 to 43% of cases.^[14-20] As per Warburg M. and Stoll C. et al. incidence of coloboma ranges from 0.5 to 2.2 cases per 10,000 live births.^[21,22] In some cases, it may be associated with systemic disorders which may be sporadic or inherited.^[23] Rarely isolated microcornea has been reported having horizontal diameter of less than 11 mm without any significant systemic disorders.^[24, 25] Ribhi Hazin and Arif O. Khan, have reported a case of bilateral small eyes in a boy of 12 years present since birth. Visual acuity with his current glasses (-3.75-3.50×020 right eye [OD], -4.25-1.25×165 left eye [OS]) was 20/40 in both eyes. No history of strabismus. Pupillary examination was normal, By Goldman tonometry, intraocular pressure was 14mm in both eyes. Slit lamp examination showed small but normal eyes having horizontal diameter of less than 10 mm of normal cornea. Anterior chamber was within normal limits.^[26] It has reported by Schubert, H.D. that in 23-42% of cases risk of retinal detachment occurs in coloboma of posterior pole.^[27]

Present study

Microcornea of right eye associated with bilateral coloboma of iris and choroid with astigmatism in both eyes associated with defective vision was seen in a young female aged 22 years. These multiple anomalies were not associated with cataract, retinal detachment, or any systemic disorders. No history of strabismus, glaucoma. Both optic discs were normal. Her vision improved after wearing glasses which is very rare.

CONCLUSION

In spite of multiple congenital defects of the eye present in this patient, her vision improved after wearing glasses which is a rare sequel. Hence it has been studied and reported.

Take home message

Any ocular congenital anomalies should be well examined, should be treated carefully and proper counseling has to be done and reassurance to be given so as to boost their morale.

REFERENCES

1. Duvall J, Miller SL, Cheattle E, Tso MO. Histopathologic study of ocular changes in a syndrome of multiple congenital anomalies. *Am J Ophthalmol*, 1987; 103(5): 701-5. PubMed PMID: 3578469.
2. Manual of ocular diagnosis and therapy Langston, Deborah P (Deborah Pavan), 1940-. 4th ed. Boston: Little, Brown, c1996. NLM ID: 9600831 [Book].
3. Ocular pathology, a text and atlas Yanoff, Myron; Fine, Ben S, 1928-. 2nd ed. Philadelphia: Harper & Row, c1982. NLM ID: 8103322 [Book].
4. Primary care of the posterior segment Alexander, Larry J. 2nd ed. Norwalk, Conn. : Appleton & Lange, c1994. NLM ID: 9315644 [Book].
5. Bermejo E, Martínez-Frías ML. Congenital eye malformations: clinical-epidemiological analysis of 1,124,654 consecutive births in Spain. *Am J Med Genet*, 1998; 75(5): 497-504. PubMed PMID: 9489793.
6. Stoll C, Alembik Y, Dott B, Roth MP. Epidemiology of congenital eye malformations in 131,760 consecutive births. *Ophthalmic Paediatr Genet*. 1992; 13(3): 179-86. PubMed PMID: 1484696.
7. Stoll C, Alembik Y, Dott B, Roth MP. Congenital eye malformations in 212,479 consecutive births. *Ann Genet*, 1997; 40(2): 122-8. PubMed PMID: 9259960.

8. Porges Y, Gershoni-Baruch R, Leibu R, Goldscher D, Zonis S, Shapira I, Miller B. Hereditary microphthalmia with colobomatous cyst. *Am J Ophthalmol*. 1992; 114(1): 30-4. PubMed PMID: 1621783.
9. Hornby SJ, Adolph S, Gilbert CE, Dandona L, Foster A. Visual acuity in children with coloboma: clinical features and a new phenotypic classification system. *Ophthalmology*. 2000; 107(3): 511-20. PubMed PMID: 10711890.
10. Macdonald AE. Causes of Blindness in Canada: An Analysis of 24,605 Cases Registered with the Canadian National Institute for the Blind. *Can Med Assoc J*, 1965; 92: 264-79. PubMed PMID: 14270210; PubMed Central PMCID: PMC1927918.
11. Fujiki K., Nakajima A., Yasuda N., Tanabe U., Kabaswa K. Genetic analysis of microphthalmos. *Ophthalmol Paed Genet*, 1982; 1: 139–149.
12. Gupta V, Gupta A, Dogra M R. Subretinal neovascularization associated with retinochoroidal coloboma. *Indian J Ophthalmol*, 1997; 45: 116-7.
13. Hyatt GA, Dowling JE. Retinoic acid. A key molecule for eye and photoreceptor development. *Invest Ophthalmol Vis Sci*, 1997; 38(8): 1471-5. Review. PubMed PMID: 9224274.
14. Daufenbach DR, Ruttum MS, Pulido JS, Keech RV. Chorioretinal colobomas in a pediatric population. *Ophthalmology*, 1998 Aug;105(8):1455-8. PubMed PMID: 9709757.
15. Gopal L, Kini MM, Badrinath SS, Sharma T. Management of retinal detachment with choroidal coloboma. *Ophthalmology*, 1991; 98(11): 1622-7. PubMed PMID: 1800922.
16. Jesberg DO, Schepens CL. Retinal detachment associated with coloboma of the choroid. *Archives of Ophthalmology*, 1961; 65(2): 163-73.
17. Morrison DA, Fleck B. Prevalence of retinal detachments in children with chorioretinal colobomas. *Ophthalmology*. 1999; 106(4): 645-6. PubMed PMID: 10201578.
18. Steahly LP. Retinochoroidal coloboma: varieties of clinical presentations. *Ann Ophthalmol*, 1990; 22(1): 9-14. PubMed PMID: 2310120.
19. Unlü N, Kocaoğlu H, Acar MA, Aslan BS, Duman S. Surgical management of retinal detachment with choroidal coloboma. *Eur J Ophthalmol*, 2002; 12(4): 299-303. PubMed PMID: 12220000.
20. Gopal L, Badrinath SS, Sharma T, Parikh SN, Shanmugam MS, Bhende PS, Agrawal R, Deshpande DA. Surgical management of retinal detachments related to coloboma of the choroid. *Ophthalmology*, 1998; 105(5): 804-9. PubMed PMID: 9593379.

21. Warburg M. Classification of microphthalmos and coloboma. *J Med Genet*, 1993; 30(8): 664-9. Review. PubMed PMID: 8411053; PubMed Central PMCID: PMC1016495.
22. Stoll C, Alembik Y, Dott B, Roth MP. Epidemiology of congenital eye malformations in 131,760 consecutive births. *Ophthalmic Paediatr Genet*, 1992; 13(3): 179-86. PubMed PMID: 1484696.
23. Pagon RA. Ocular coloboma. *Surv Ophthalmol*, 1981; 25(4): 223-36. Review. PubMed PMID: 6782689.
24. Batra DV, Paul SD. Microcornea with myopia. *Br J Ophthalmol*, 1967; 51(1): 57-60. PubMed PMID: 6018552; PubMed Central PMCID: PMC506327.
25. Batra DV, Paul SD. Unilateral microcornea and enophthalmos with bilateral anterior and posterior anomalies. *Br J Ophthalmol*, 1967; 51(9): 627-9. PubMed PMID: 4963695; PubMed Central PMCID: PMC506457.
26. Hazin R, Khan AO. Isolated microcornea: case report and relation to other "small eye" phenotypes. *Middle East Afr J Ophthalmol*, 2008; 15(2): 87-9. doi: 10.4103/0974-9233.51999. PubMed PMID: 21346844; PubMed Central PMCID: PMC3038115.
27. Schubert HD. Structural organization of choroidal colobomas of young and adult patients and mechanism of retinal detachment. *Trans Am Ophthalmol Soc*, 2005; 103: 457-72. PubMed PMID: 17057813; PubMed Central PMCID: PMC1447584.