

MACROADENOMA IN PREGNANCY, SUCCESSFUL MANAGEMENT WITH CABERGOLINE: A CASE REPORT.

Pinky Jena*, Shilpa Venkatesh and Vani Ramkumar

Dept. of Obstetrics & Gynecology, St. Johns medical College, Bangalore, Karnataka, India.

Article Received on
24 April 2015,

Revised on 18 May 2015,
Accepted on 09 June 2015

***Correspondence for
Author**

Dr. Pinky Jena

Dept. of Obstetrics &
Gynecology, St. Johns
medical College,
Bangalore, Karnataka,
India.

ABSTRACT

Hyperprolactinemia is a common cause for anovulation and infertility. When evaluated appropriately and treated with dopamine agonist, pregnancy can be achieved easily. Here, we report the case of a 25 year old nulliparous lady who presented to us with secondary amenorrhea and was diagnosed to have pituitary macroadenoma. Cabergoline was initiated and the patient conceived within three months. After conception, cabergoline was discontinued and bromocriptine was initiated. Due to nontolerance, patient was restarted on cabergoline that was continued till delivery. It was stopped postpartum to allow for lactation. The lady and her infant are under follow up. **Conclusion:** Cabergoline may be used safely and effectively during pregnancy to

treat macroadenoma without causing any fetal malformations. By this case report, we hope to contribute to the relatively meagre data available on use of cabergoline in pregnancy and its outcome.

KEYWORDS: Hyperprolactinemia, Macroadenoma, Bromocriptine & Cabergoline.

INTRODUCTION

Prolactin secreting adenomas are the most commonly encountered pituitary tumors in women of childbearing age. Hyperprolactinemia interferes with the hypothalamo - pituitary- ovarian axis at various levels and is responsible for about a third of all cases of female infertility.^[1] With adequate management with dopamine agonists, most women are expected to achieve successful pregnancies. At present, there appears to be more outcome data available with bromocriptine as compared to cabergoline on incidence of abortions, preterm labor, congenital malformations. Cabergoline has higher effectiveness in prolactin suppression and tumor reduction. It is also the drug of choice in case of nontolerance to bromocriptine. In our

patient, we have used cabergoline successfully to achieve ovulation and later during pregnancy for control of symptoms, without any evidence of fetal malformations.

CASE REPORT

A 25 year old nullipara presented to the Department of Obstetrics and Gynecology of St. John's Medical College and Hospital with secondary amenorrhea for 9 months. She had headache but no visual disturbance. General, systemic and abdominopelvic examination were normal, except for hirsutism. There was no expressible galactorrhea. The serum prolactin > 200 ng/dl and MRI revealed a 3.0X2.3X2.4 cm pituitary macroadenoma with extension into the sphenoid sinus, suprasellar extension and splaying of optic chiasma. Visual perimetry was normal and serum cortisol was 0.9 ng/dl. She was married for five years. She conceived but had missed abortion at 15 weeks. In 2010, she received 2 more cycles of ovulation induction with no response and developed secondary ammenorhea, when she presented to us.

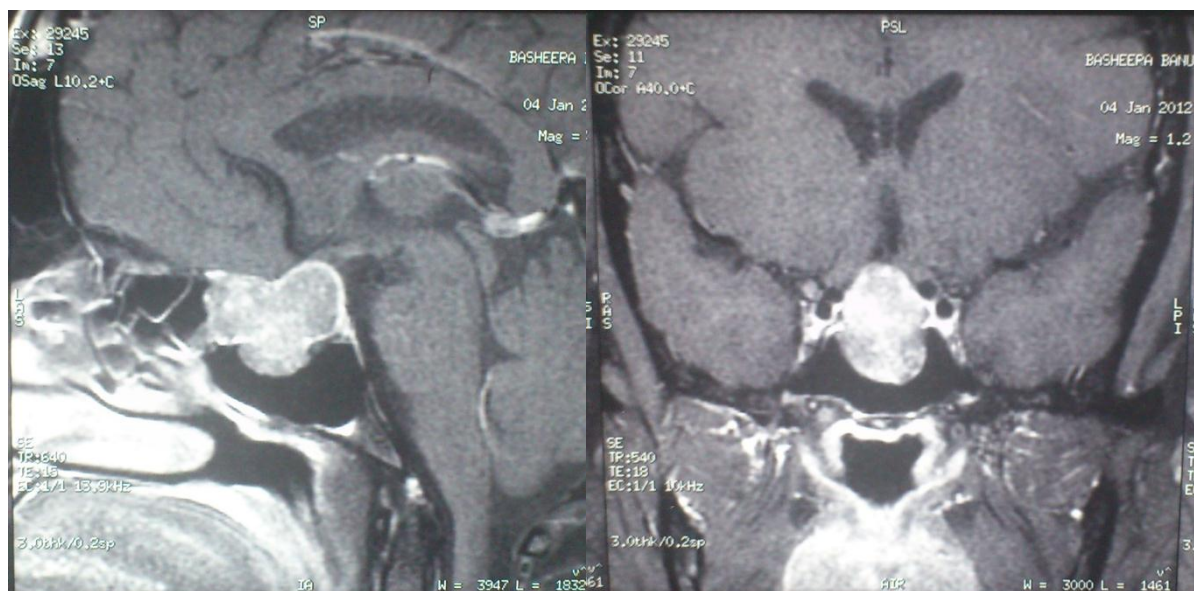


Fig1: MRI Pictures of pituitary macroadenoma

Endocrinological and neurosurgical opinion were sought. She was started on cabergoline 0.5 mg twice weekly and she conceived within 3 months. Once pregnancy was confirmed, cabergoline was discontinued and bromocriptine 1.25 mg daily was initiated. In first trimester, she developed non-tolerance to bromocriptine. Hence it was stopped and patient was restarted on cabergoline 0.25 mg once a week till delivery. The antenatal period was uneventful and patient was monitored with regular visual perimetry and serum cortisol levels. Labor was induced at 38 weeks as patient developed preeclampsia. She underwent a cesarean delivery due to failed induction and delivered a healthy female baby weighing 3 kg.

Cabergoline was withheld following delivery to allow for lactation and breastfeeding was well established.

DISCUSSION

Hyperprolactinemia may present as a clinical spectrum ranging from luteal phase defect to anovulation to amenorrhea. It causes secondary amenorrhea in 30% of cases due to inhibition of pulsatile GnRh secretion. Approximately 80% of hyperprolactinemic women, with or without adenoma, achieve pregnancy with dopamine agonist treatment. Cabergoline, a selective dopamine receptor type 2 agonist, has fewer side effects, greater potency, and is more effective than bromocriptine in restoring normal prolactin levels in women with lactotroph adenomas.^[2] Since our patient had pituitary macroadenoma > 3 cm in size she was started on cabergoline. Following pregnancy, cabergoline was stopped and bromocriptine started as it appears to be safer in pregnancy. In more than 2400 pregnancies, bromocriptine has been used without any increase in spontaneous abortions, multiple pregnancies or congenital malformation.^[3]

In patients who are resistant to bromocriptine, as well as in patients who experience side effects, cabergoline appears to be the drug of choice. Outcome data available in more than 300 pregnancies in which cabergoline was administered to facilitate ovulation induction, and during pregnancies did not show increased risk of ectopic or multiple birth deliveries or malformation.^[4] Since our patient developed non-tolerance she was restarted on cabergoline in late first trimester. Due to stimulatory effects of pregnancy on the normal lactotrophs, enlargement of the normal pituitary can be expected (Up to double its size by the third trimester) the risk of clinically significant growth with microadenomas is extremely low (only approximately 1-2%).

The risk is approximately 15-20% in those with macroadenomas. Nevertheless, serial prolactin levels during pregnancy may be unnecessary as serum prolactin levels during pregnancy are raised. The prolactin levels in normal pregnancy are 20-40 ng/ml at the end of first trimester, 50-150 ng/ml and 100-400 ng/ml at the end of second and third trimester respectively. In women with significant tumour growth during pregnancy, headaches usually precede visual disturbances. Symptoms typically regress promptly after dopamine agonist treatment.

There are three approaches for the management of macroadenoma in pregnancy. For large macroadenomas, patient may undergo transphenoidal surgery prior to pregnancy, but it poses the risk of hypopituitarism which may further aggravate the problem of infertility. Incomplete resection of the tumor and persistent hyperprolactinemia are unfortunately common. Second approach is to use bromocriptine to allow for ovulation, and to discontinue it once pregnancy is achieved. Patient needs to be monitored for evidence of tumor growth during pregnancy.

The third approach is to continue bromocriptine throughout pregnancy. In previously symptomatic patients with suprasellar extension, continuation of bromocriptine throughout is prudent, since sudden re-expansion of tumor has been documented surgery is rarely necessary.^[6,7] Our patient had headache prior to pregnancy and had suprasellar extension of the tumor, hence it was decided to continue dopamine agonist throughout pregnancy.

Breastfeeding poses no significant risk for tumor growth with microadenoma or macroadenoma that remain asymptomatic during pregnancy, but is contraindicated for those with neurological symptoms at the time of delivery. Dopamine agonist treatment should not be resumed until after cessation of lactation.

CONCLUSION

Hyperprolactinemia when appropriately treated with dopamine agonist leads to pregnancy. Pregnancy can be safely and effectively managed with dopamine agonist. Pregnant women with macroadenoma require clinical assessment and serial visual field testing. In our case, cabergoline was used without any evidence of fetal malformation.

REFERENCES

1. Marc A Fritz, Leon Speroff. Clinical gynecologic endocrinology and infertility. 8th edition, 2011.
2. Webster J, Piscitelli G, Polli A, Ferrari Cl, Ismail J, Scanlon M R. A comparison of cabergoline and bromocriptine in the treatment of hyperprolactinemia amenorrhea N Engl J Med, 1994; 333: 904-9.
3. Krupp P, Monka C: Bromocriptine in pregnancy: safety aspects Klin Wochenschr., 1987; 65: 823 – 827.
4. Colao A, Abs R, Barcena DG, Chanson P, Paulus W, Kleinbey DL. Pregnancy outcomes for cabergoline treatment: extended results from a 12 year observational study Clin Endocrinol., 2008; 68: 66- 71.

5. Molitch ME : Prolactinomas and pregnancy. Clin Endocrinol., 2010; 73: 147 – 148.
6. Bernard Corenblum. Pituitary disease and pregnancy.
7. Syed Ali Imran, Managing prolactin – secreting adenomas during pregnancy. Canadian family physician., April 2007; 53(4): 653-658.
8. Hira Shahzad, Aisha Sheikh and Lumaan Sheikh. Cabergoline therapy for macroprolactinoma during pregnancy: a case report. BMC research notes., 2012; 5: 606.
9. Sukhwinder Kaur Bajwa, Sukhminder Jit Bajwa, Praveen Mohan and Anita Singh. Management of prolactinoma with cabergoline treatment in a pregnant woman during her entire pregnancy. Indian J Endocrinology and metabolism., Sep-2011; 15(Supply 3): S 267 – 5270.
10. Turkali J, Braun P, Krunn P. Surveillance of bromocriptine in pregnancy. JAMA., 1982; 247: 1589 – 91.