

DI-HERBAL MIXTURE OF *ALSTONIA BOONEI* AND *ANNONA SQUAMOSA* AMELIORATES PARACETAMOL (PCM) INDUCED HEPATOTOXICITY IN MICE

Onwusonye J.C.*¹, Okore S.A.² and Patrick-Iwuanyanwu K.C.³

¹*Department of Microbiology/Biochemistry, Federal Polytechnic, Nekede, Imo State
Nigeria.

²Department of Chemistry/Biochemistry, Federal Polytechnic, Nekede, Imo State Nigeria.

³Department of Biochemistry, University of Port Harcourt, Rivers State, Nigeria.

Article Received on
09 March 2017,

Revised on 29 March 2017,
Accepted on 19 April 2017

DOI: 10.20959/wjpr20175-8095

*Corresponding Author

Dr. Onwusonye J.C.

Department of
Microbiology/Biochemistry,
Federal Polytechnic, Nekede,
Imo State Nigeria.

ABSTRACT

Alstonia boonei and *Annona squamosa* are two herbs commonly used in Nigerian folk medicine for the management of conditions ranging from malaria to general feverish conditions. In this study, the synergistic effect of both herbs on paracetamol-induced hepatotoxicity was examined. Twenty male swiss albino mice (26-28g) were randomly distributed into five groups of four mice per group. The first group (normal control) was administered with normal saline at a dose of 5ml/kg body weight while animals in groups 2-5 were intoxicated with paracetamol administered as a single oral dose of 2500mg/kg body weight. In the next phase of the treatments, animals in groups 1

and 2 were maintained on distilled water, mice in group 3 were treated with silymarin (25mg/kg body weight), while mice in groups 4 and 5 (test groups) were treated with herbal mixture at respective doses of 250 and 500 mg/kg body weight. Treatment lasted for fourteen days. On the 15th day, all mice were sacrificed and blood samples taken for measurement of biochemical and haematological parameters. Liver tissue samples were also examined for antioxidant parameters as well as histopathology. Results showed that at the two doses of the herbal mixture, liver features were preserved comparable to that of mice treated with standard silymarin. It was thus concluded that the di-herbal mixture exhibits hepatoprotective effects on paracetamol intoxicated subjects.

KEYWORDS: *Alstonia boonei*, *Annona squamosa*, paracetamol, hepatotoxicity.

1.0 INTRODUCTION

The liver is a very vital body organ responsible for the metabolism of endogenous and exogenous substances. It plays an essential role in the detoxification of xenobiotics. In its attempt to perform these roles the liver sometimes faces some toxic challenges from any of xenobiotic, infections, alcohol, malnutrition and medications. Paracetamol is a widely used analgesic and antipyretic which produces symptoms of hepatic damage at very high doses. Toxicity in some cases is directly related to drug metabolism. Acetaminophen is metabolized primarily by Sulphation and glucuronidation of the Para-hydroxyl group. The hepatic damage in rats is due to a small fraction of administered dose of acetaminophen which is converted to a reactive metabolite by mixed function oxidase enzymes present in hepatic cells. After a normal dose of acetaminophen, the small amount of reactive metabolite produced is detoxified by preferential conjugation with cellular glutathione and excreted in the urine. Neither unchanged Acetaminophen nor its glucuronide and sulphate conjugates are toxic. Thus acetaminophen could be a remarkable safe drug when administered to rats and mice at yet to be determined therapeutic doses. This hepatotoxicity has been attributed to the formation of highly toxic reactive metabolite known as n-P-acetylparabenzoquinoneimine. In spite of the increasing rate of morbidity and mortality worldwide arising from liver diseases, available therapeutic agents for hepatic conditions have remained limited, thus the need for effective drugs (Akindele *et al*, 2010). Many products of plant origin however abound which have proved potent in the management of liver diseases (Mitra *et al*, 2000).



Fig.1. Picture of *Alstonia Boonei De Wild*

Alstonia is a wide spread genus of evergreen trees and shrubs from the dogbane family (*Apocynaceae*). The species *Alstonia boonei* is commonly known in English as cheesewood, pattern wood or stool wood. The Igbos of South east Nigeria call it *egbu*, while the Yorubas

of south west Nigeria know it as *ahun*. *Alstonia boonei*, as a plant has many practical and diverse uses. The stem bark of *A. boonei* has diuretic, spasmolytic and hypotensive properties. An infusion of the stem bark of *A. boonei* in cold water is drunk as a cure for venereal diseases, worms, snake bite, rheumatic pains and to relax muscles. (Oliver, 1986). An infusion of roots and stem bark is drunk as a remedy for asthma while a liquid made from the stem bark and fruits is drunk once daily to treat impotence. In Ghana, a decoction of the bark is given after child birth to help the delivery of the placenta (Oliver, 1986).

A decoction of the stem bark is taken by the Ikeduru people of Imo State south-east Nigeria as a strong remedy for malaria.



Fig. 2: Picture of *Annona squamosa* Linn. (Fruits on a branch)

Annona squamosa commonly known as custard apple or sweet sop is a semi-evergreen shrub or small tree reaching 6-8meters (20-26ft) tall. The plant is a native of tropical America and the West-Indies, but its original home is uncertain. *Annona Squamosa* has a wide array of ethno botanical uses. Fruits are normally eaten fresh. The roots are cathartic and purgative. The tree is a good source of firewood. Green fruits, seeds and leaves have effective vermicial and insecticidal properties. The plant is traditionally used for the treatment of epilepsy, dysentery, cardiac problems, worm infestation, constipation, haemorrhage, bacterial infection, fever and ulcer. (Kirtika *et al.*,1957).

2.0 MATERIALS AND METHODS

2.1 Collection and Identification of Plant Materials

i) *Alstonia boonei*: Root bark and leaves were collected from a tree at Amaimo in Ikeduru Local government area of Imo State, South East Nigeria.

ii) ***Annona squamosa***: Fresh and healthy leaves of *Annona squamosa* were collected from a tree at Ihiagwa in Owerri West Local government area of Imo State, South-East Nigeria. The plant materials were identified by a taxonomist in the department of Biotechnology Federal University of Technology Owerri.

2.2 PREPARATION OF PLANT MATERIALS

i. ***Alstonia boonei***: The fresh root bark of *Alstonia boonei* were sorted to get rid of dead matters and other unwanted materials. These were subsequently cleaned, cut into pieces and air dried under shed for two weeks. After drying, the root barks were ground in a mortar to get a coarse powder which was subsequently milled in a blender to a fine powder.

ii. ***Annona squamosa***: The fresh and healthy leaves of *Annona squamosa* were dried under shade for one week. The samples were subsequently ground to fine powder.

2.2 Formulation of herbal mixture

Two hundred and fifty grams of each ground plant sample was separately measured out and subsequently mixed together in a conical flask to give 500g of di-herbal powder. This was soaked in 1500mls of 95% methanol for 72hours, at the end of which filtration was done. The filtrate was concentrated to a gel in a rotary evaporator at 45–50°C.

2.3 Animal Management

Twenty Swiss albino mice were used for the study. These were procured from the animal holdings of Biochemistry Department, University of Port Harcourt Nigeria. The animals were kept for 7days prior to commencement of study for acclimatization with Laboratory conditions. Animal housing was maintained at a temperature of $23 \pm 2^{\circ}\text{C}$ and with a 12hr light/12hr darkness cycle. The animals were allowed free access to commercial feed pellets and clean drinking water. The United States National Institute of Health Principles of Laboratory Animals Care (NIH, 1978) were adhered to in the study.

2.4 ACUTE TOXICITY

The oral median lethal dose (LD_{50}) values of both plants have been reported in mice to be $>5000\text{mg/kg}$ body weight (Onwusonye *et al.*, 2014a, Onwusonye *et al.*, 2014b).

2.5 EFFECT OF DI-HERBAL MIXTURE ON PARACETAMOL INTOXICATED MICE

The experimental animals were randomly divided into 5 groups of 4 mice each. Care was taken to ensure even distribution of animal weight in all the groups. Animals in group 1 served as normal control and were treated with normal saline at a dose of 5m/kg body weight. Animals in groups 2 – 5 were intoxicated with paracetamol administered at a single dose of 2500mg/kg body weight as an oral suspension.

Treatments continued on all mice in the following order: Mice in group 1(normal control) continued to receive distilled water. Group 2 animals served as pathological control and were also maintained on distilled water. Mice in group 3(standard control) were treated with silymarin at a dose of 25mg/kg body weight, while mice in groups 4 and 5(test groups) were treated with the herbal mixture at dose levels of 250mg/kg and 500mg/kg body weight respectively. Each treatment was given once daily for 14 consecutive days. On the 15th day, all mice were sacrificed under the influence of chloroform vapour as anaesthesia. Blood samples were collected via cardiac puncture for the evaluation of biochemical markers of hepatic function as well as heamatological parameters. Liver tissues were excised from the sacrificed mice for the evaluation of liver antioxidant parameters and histopathological examinations.

2.5.1 Preparation of Serum

Whole blood samples for haematological studies were collected in EDTA anticoagulant bottles while samples for biochemical studies were taken in plain sample bottles. Serum was separated by centrifugation at 600xg for 10min and analyzed for various biochemical indices. Storage of the sera was done in a refrigerator prior to analysis. The red blood cells and white blood cells were determined by means of an auto haematology analyzer. Serum aspartate amino transferase (AST), alanine aminotransferase (ALT), alkaline phosphate activities as well as serum total protein were determined using standard methods.

2.5.2 Preparation of Liver Homogenate Sample

Liver tissues were homogenized in 10% w/v of 0.1M phosphate buffer and spun at 12,000xg for 10minutes. The supernatant was siphoned and used for the evaluation of enzymatic and non enzymatic antioxidants of the liver.

Determination of antioxidant activities

Enzymatic antioxidants were evaluated by monitoring superoxide dismutase (SOD), glutathione peroxidase (GPx) and catalase activities. Non enzymatic antioxidant was evaluated by monitoring the levels of reduced glutathione(GSH).

2.5.4 Histological Examinations

At the end of experimental period, animals were sacrificed and the liver samples were carefully excised and fixed in 4% formaldehyde for histopathological studies according to the method described by Akparie (2004). The liver samples were sliced and washed in saline solution. The sliced samples were processed and embedded in paraffin wax. Sections were taken and stained with haematoxylin and eosin. After preparations, samples were viewed and photographed using x400 objective of microscope equipped with digital camera.

2.6 Statistical Analysis

Data obtained were subjected to analysis of variance (Steel and Torries,1980) implemented in SPSS statistics 17.0(SPSS Inc.,2008). The means were separated using Duncan Multiple Range Test at the 0.05 level of significance.

3.0 RESULTS

3.1 Effect of herbal mixture on haematological parameters of paracetamol intoxicated rats

The effect of di- herbal mixture of *A. boonei* and *A. squamosa* at the dose levels of 250 and 500 mg/kg body weight on some haematological parameters of paracetamol intoxicated mice is shown in Table 1, The hepatic stress induced by paracetamol over dose resulted to a decrease in haemoglobin(Hb), total red and white blood cells counts. At the 500mg/kg dose level of the herbal formula, significant increase ($p < 0.05$) in erythrocyte count was obtained (11.6 ± 0.3).

Table1: Effect of herbal mixture of *A. boonei* and *A. squamosa* on haematological parameters of paracetamol intoxicated mice.

| Group | Haemoglobin(g/dl) | RBC count ($\times 10^6/\mu\text{L}$) | PCV(%) | Total WBC count ($\times 10^9/\text{L}$) |
|----------------|-------------------|---|------------------|--|
| 1(control) | 11.3 ± 0.1^a | 12.2 ± 0.6^a | 33.6 ± 0.5^a | 6900 ± 0.9^a |
| 2(paracetamol) | 5.1 ± 0.9^b | 8.3 ± 0.1^b | 15.0 ± 0.1^b | 2200 ± 1.2^b |
| 3(silymarin) | 10.1 ± 1.0^a | 11.8 ± 0.9^a | 31.2 ± 0.8^a | 5500 ± 2.0^a |
| 4(250mg/kg) | 9.4 ± 1.8^a | 10.5 ± 0.1^a | 27.6 ± 2.1^a | 4600 ± 2.1^a |
| 5(500mg/kg) | 9.6 ± 1.5^a | 11.6 ± 0.3^a | 30.1 ± 0.2^a | 5300 ± 1.3^a |

Values are Mean \pm SEM (n=4).

a, b: Values in the same column with different superscripts are significantly different ($p < 0.05$)

3.2 Effect of Diherbal mixture of *A. boonei* and *A. squamosa* on Serum biochemical markers in Paracetamol intoxicated mice

The effect of the diherbal mixture on biochemical parameters of paracetamol intoxicated mice is shown in table 2. Injury to the Hepatocytes Results to elevations in the Serum activities of Aspartate aminotransferase (AST), Alanine aminotransferase (ALT) and alkaline phosphate (ALP). Treatment with the herbal mixture resulted to serum enzyme activities comparable to the reference standard silymarin (25mg/kg). At the highest herbal dose of 500mg/kg, AST activity was 94.52 ± 1.1 i.u/L, ALT was 73.4 ± 0.3 i.u/L while ALP activity was 173.3 ± 0.9 i.u/L.

Serum total protein level was 6.8 ± 0.1 g/dl.

Table 2: Effect of Diherbal Mixture of *A. boonei* and *A. Squamosa* and some biochemical parameters of paracetamol intoxicated mice

| | AST (i.u/L) | ALT (i.u/L) | ALP (i.u/L) | Total Protein (mg/dl) |
|-----------------------|-----------------|-----------------|-----------------|--------------------------|
| Group 1 (Control) | 40.69 ± 0.2 | 28.6 ± 0.4 | 137.8 ± 0.3 | 10.0 ± 0.5 |
| Group 2 (Paracetamol) | 164.4 ± 0.3 | 142.3 ± 0.2 | 230.6 ± 0.7 | 3.1 ± 0.1 |
| Group 3 (Silymarin) | 60.5 ± 0.2 | 42.4 ± 0.1 | 145.8 ± 0.3 | 8.5 ± 0.1 |
| Group 4 (250mg/kg) | 130.4 ± 0.1 | 113.3 ± 0.1 | 203.5 ± 0.6 | 5.3 ± 0.6 |
| Group 5 (500mg/kg) | 94.52 ± 1.1 | 78.4 ± 0.3 | 173.3 ± 0.9 | 6.8 ± 0.1 |

3.3 Effect of Di-herbal mixture on antioxidant parameters in Paracetamol intoxicated mice.

Administration of Paracetamol at the dose of 250mg/kg resulted to decreased enzymatic and non enzymatic antioxidants as shown in Table 3.

Table3: Effect of Diherbal Mixture of *A. boonei* and *A. Squamosa* on selected antioxidant levels in paracetamol intoxicated mice

| | SOD (Units/Min/mg) Protein | CAT (μ moles of H_2O_2 consumed/min/mg protein) | GP _x (mg GSH consumed/min/mg protein) | GSH (μ mole of GSH/mg) Protein |
|---------|----------------------------------|---|---|--|
| Group 1 | 0.51 | 189.2 | 28.6 | 23.1 |
| Group 2 | 0.13 | 36.5 | 8.3 | 11.6 |

| | | | | |
|----------------|------|-------|------|------|
| Group 3 | 0.49 | 156.3 | 25.3 | 19.5 |
| Group 4 | 0.22 | 125.0 | 18.7 | 13.8 |
| Group 5 | 0.34 | 139.6 | 23.9 | 17.6 |

3.3 Histopathological examinations

The hepatic damage caused by paracetamol over dose is shown in Plate 1. Paracetamol treated mice liver showed severe distortion of the hepatocytes with necrotic lesions. The herbal treated mice showed liver features relatively preserved comparable to the normal and standard control mice (Plates 2 – 4).

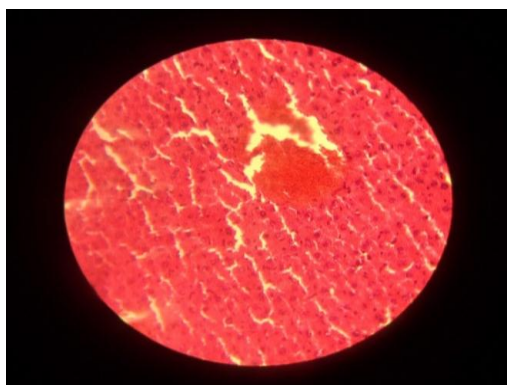


PLATE 1: Photomicrograph of liver of mice intoxicated with paracetamol (untreated) showing distorted hepatic cyto-architecture (H&EX400)

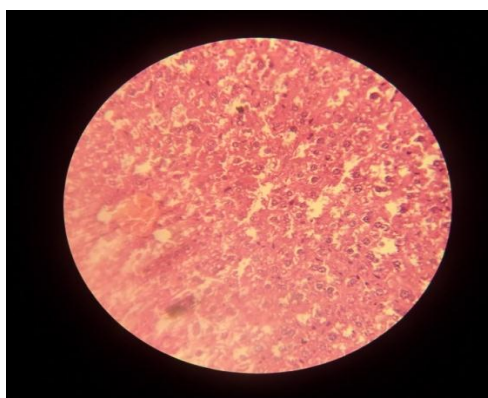


PLATE 3: Photomicrograph of liver of PCM intoxicated mice treated with herbal mixture (250mg /kg body weight) showing well preserved hepatocytes (H&EX400)

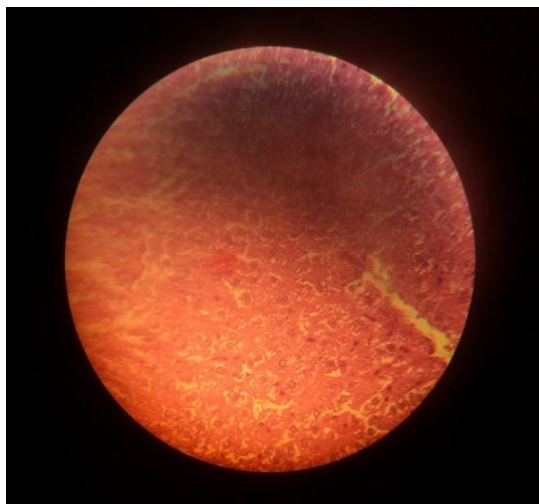


PLATE 2: Photomicrograph of liver of PCM intoxicated mice treated with silymarin(25mg /kg body weight) showing normal hepatic cyto-architecture (H&EX400)

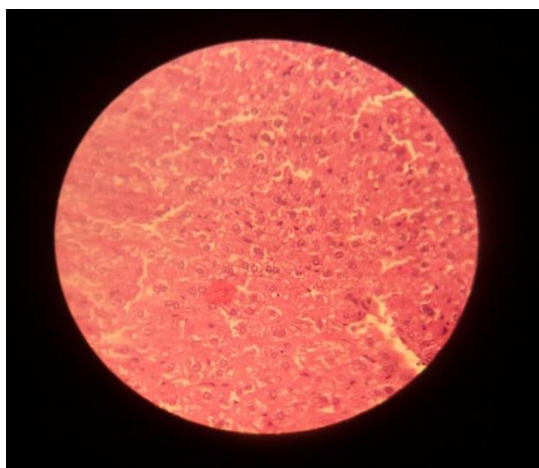


PLATE 4: Photomicrograph of liver of PCM intoxicated mice treated with herbal mixture (500mg /kg body weight) showing well preserved hepatocytes (H&EX400)

4.0 DISCUSSION

The liver which is the largest mammalian internal organ plays a vital role in metabolism, detoxification and inflammatory response (Tacke *et al.*, 2009). The organ is primarily charged with the responsibility of regulating the internal chemical environment. In attempt to perform this function the liver is at most times faced with toxic challenges which may have great negative consequences. Paracetamol or acetaminophen, chemically known as N-acetyl-p-aminophenol is a well know analgesic and antipyretic drug. Paracetamol over dose has been reported to lead to acute liver failure and hepatic cytolysis (Michaut *et al.*, 2014). Hepatotoxic agents reduce the functional integrity of liver hepatocytes. Impairment of functionality of liver cells results to accumulation of waste products of metabolism such as

ammonia in the blood (Mao *et al.*, 2014), Ravichandran *et al.*,(2014). Paracetamol induced hepatotoxicity has been reported to occur by covalent binding of its metabolite n-acetyl-p-benzoquinoneimine to the sulfhydryl group of protein leading to lipid peroxidation and cell necrosis (Kapur *et al.*, 1994), Ravichandran *et al.*,(2014). When the cells of the liver are damaged, biochemical marker enzymes like AST, ALT and Alkaline phosphatase find their ways as a result of leakage through compromised plasma membranes. This results to increased activities of the enzymes in the serum. Silymarin, used as standard control is an established hepatoprotective agent obtained from *Silybum marianum*. It has been reported to exert a protective effect on the membrane of hepatic cells (Ramellini and Meldosi, 1976). Administration of di-herbal mixture at doses of 250 and 500mg/kg in this study resulted to significant reduction of the paracetamol induced elevation of AST, ALT and Alkaline phosphatase comparable to the effects of Silymarin. Injury to the liver tissue induced by paracetamol intoxication caused a decrease in red blood cells (RBC) count, Haemoglobin, Packed Cell volume and total white blood Cell count. Treatment with the herbal mixture at the doses of 250 and 500mg/kg increased the level of haemoglobin, Packed Cell Volume and erythrocyte counts also pointing to amelioration of the acetaminophen induced hepatic stress. These elevations of haematological parameters should not be unexpected since the liver also performs the function of synthesis of red blood cells. The elevation of Haemoglobin Packed Cell Volume, Erythrocyte Count observed in mice treated with herbal mixture was very comparable to that observed with Silymarin, the positive standard. This suggests that the herbal mixture has marked hepatoprotective effect. The observed elevation in serum total protein levels of paracetamol intoxicated rats treated with herbal mixtures as compared with both those treated with standard Silymarin and those left untreated equally indicate that the herbal mixture has marked potency against paracetamol induced hepatic injury. The suggested ameliorative effect of di-herbal mixture of *A. boonei* and *A. squamosa* on acetaminophen induced liver damage is further confirmed by results obtained from the histological examinations. Histological studies revealed severe distortion of hepatocytes and marked necrosis in the liver of mice intoxicated with paracetamol (**Plate 1**).

Mice treated with herbal mixture however presented liver histological features comparable to those in the control (normal and standard) groups. (Plates 2-4).

5. CONCLUSION

Results of this study have shown that the herbal mixture of *Alstonia boonei* and *Annona squamosa* (BN + SL 1:1) is safe and exerts no toxic effect in mice up to the maximum dose used. Serum biochemical markers of hepatic function were maintained at levels very comparable to the control groups. Hepatic antioxidants markers were significantly elevated close to values obtained with normal control groups. Histological studies of liver tissues indicate that both silymarin and the herbal mixture of BN + SL (1:1) have protective effects over acetaminophen induced hepatic damage. The herbal mixture of *Alstonia boonei* and *Annona squamosa* can thus be used as a source of basic principles in the formulation of standard hepatoprotective drugs.

REFERENCES

1. Akindele A.J., Ezenwanebe K.O., Anunobi C.C. and Adeyemi O. O. (2010). Hepatoprotective and *in vivo* antioxidant effects of *Byrsocarpus coccineus* Schum and Thonn (Connaraceae). *J. Ethnopharmacol* 129: 46-52.
2. Akparie S. O. (2004). General Veterinary Pathology, 1st edition, Stirling Horden Publishers (Nig.) Pg. 136.
3. Kapur V., Pillai K. K., Hussian S. Z. and Balani D. K. (1994). Hepatoprotective activity of "Jigrine" on liver damage caused by alcohol-CCL4 and Paracetamol in rats. *Indian J. Pharmacol.* 26: 35-40.
4. Kirtika K. R; and Basu B. D. (1957). Indian Medicinal Plants 2nd Ed. Vol. 1 Pp. 66-69.
5. Michaut A., Moreau C., Robin M. A. and from entry B. (2014). Acetaminophen induced liver injury. *Clin-Rev. Allergy Immunol.* 36: 4-12.
6. Mitra S.K., Seshadri S.J., Venkatar anganna M.V., Gopumadhavan S., Udupa V. and Sarma D. N. K. (2000). Effect of HD-03- a herbal formulation in galactosamine – induced hepatopathy in rats. *Indian J. Physiol Pharmacol.* 44: 82-86.
7. Oliver B. D. (1986). Propagation and management, functional uses of medicinal plants in: Medicinal plant, Tropical West Africa. Cambridge University Press Pg. 89-90.
8. Onwusonye J. C., Uwakwe A. A. and Patrick Iwuanyanwu K. C. (2014). Acute and Subacute toxicity studies of methanol leaf extracts of *Amona squamosa* Linn. in Mice. *Sky Journal of Biochem. Res.* 3(7): 053-059.
9. Onwusonye J. C., Uwakwe A. A., Iwuanyanwu P and Muritala I. K. (2014). Oral acute Toxicity (LD50) Study of methanol extracts of *Alstonia boonei* root bark in mice. *Int. J. Innov. Res. and Dev.* 3(7): 227-229.

10. Ramellini G. and Meldozzi J. (1976). Liver protection by Silymarin. *In Vitro* effect on dissociated rat hepatocytes. *Arzneim Forsch (Drug Research)* 26: 69:73.
11. Ravichandran S., Rahul C. and Thangaraj P. (2014). Hepatoprotective effect of *Rhodiola imbricata* rhizome against paracetamol-induced liver toxicity in rats. *Saudi J. Biol. Sci.* 2(5): 409-416.
12. Tacke F., Luedde T. and Trautwein C. (2009). Inflammatory pathways in liver homeostasis and liver injury. *Clin. Rev. Allergy Immunol.* 36: 4-12.