

**CHOLECYSTOENTERIC FISTULA- A RARE CAUSE OF
GASTROINTESTINAL BLEEDING****Dr. Sabade Pradnya Prakash***

Assistant Professor, Dept of Surgery R. A. Podar Ayurved Medical College, Worli,
Mumbai -18.

Article Received on
18 June 2017,

Revised on 09 July 2017,
Accepted on 30 July 2017

DOI: 10.20959/wjpr20178-9139

Corresponding Author*Dr. Sabade Pradnya
Prakash**

Assistant Professor, Dept of
Surgery R.A. Podar Ayurved
Medical College, Worli,
Mumbai-18.

ABSTRACT

A 60-year-old woman presented to the emergency department of our hospital for several episodes of upper gastro-intestinal bleeding (hematemesis and melena). The endoscopic examination (Figure 1) showed a large ulcer at the front of the bulb, with a calculation within it and a visible vessel on the banks of the ulcer treated by putting two clips. Computer tomography (CT), demonstrated a sclerotic, atrophic and multi gallstone gallbladder, with a calculation protruding in the duodenum. The patient underwent surgery which consisted on partial cholecystectomy with duodenal suture and closing of cystic duct.

KEYWORDS: Gastrointestinal Bleeding, Cholecystoenteric Fistula.**1. INTRODUCTION**

Acute upper gastrointestinal bleeding is a common medical emergency that could involve the vital prognosis. The etiologies are many: some are common, others are rare. Among the very rare etiologies, the fistulas whose diagnosis can be done by endoscopy and imaging and treatment is usually surgical.

2. CASE REPORT

A 60-year-old woman presented to the emergency department of our university hospital for several episodes of upper gastro-intestinal bleeding (hematemesis and melena), the first of which dated to 3 days. On examination, hemodynamic parameters were correct. At admission, her haemoglobin was 6.9 g/dl, platelet count 213.000/mcl, prothrombin time 87% and liver test didn't show any abnormality. The endoscopic examination (Figure 1) showed a

large ulcer at the front of the bulb, with a calculation within it and a visible vessel on the banks of the ulcer treated by putting two clips to prevent bleeding recurrence.

Computer tomography (CT), demonstrated a sclerotic, atrophic and multiple gallstones in gallbladder, with a calculation protruding in the duodenum (Figure 2). Several mechanisms have been reported in the literature explaining.

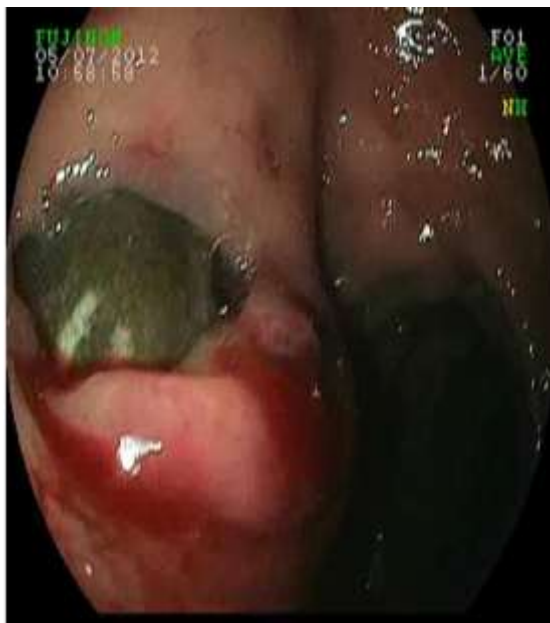

Figure 1: Large ulcer at the front of the bulb with a calculation within it.

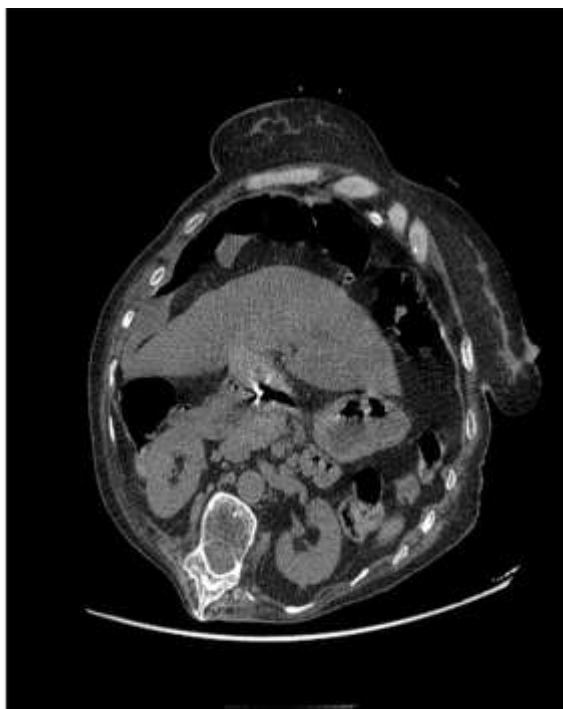


Figure 2: Sclerotic, atrophic gallbladder, with a calculation protruding in the duodenum.

The appearance of this kind of fistula, including pseudoaneurysm and haemobilia [1] -[3] . The patient underwent surgery which consisted on partial cholecystectomy with duodenal suture and closing of cystic duct.

3. CONCLUSION

Via this case, we want to attract attention to this rare cause of gastrointestinal bleeding, and we emphasize the importance of careful endoscopic examination in upper gastrointestinal bleeding to be able to reveal this kind of causes. CT performed by an expert can help in diagnosis. Surgery is the standard treatment for this cause of upper gastrointestinal bleeding.

4. Study Highlights

- Bilio-digestive fistula as rare disease.
- Bilio-digestive fistula as a rare cause of gastrointestinal bleeding.
- The importance of careful endoscopy.
- The importance of imaging (CT).
- Surgery as the standard treatment.

REFERENCES

1. Saluja, S.S., Ray, S., Gulati, M.S., Pal, S., Sahni, P. and Chattopadhyay, T.K. Acute Cholecystitis with Massive Upper Gastrointestinal Bleed: A Case Report and Review of the Literature. BMC Gastroenterology, 2007; 7: 12. <http://dx.doi.org/10.1186/1471-230X-7-12> [Citation Time(s):1].
2. Nana, G.R., Gibson, M., Speirs, A. and Ramus, J.R. Upper Gastrointestinal Bleeding: A Rare Complication of Acute Cholecystitis. International Journal of Surgery Case Reports, 2013; 4: 761-764. <http://dx.doi.org/10.1016/j.ijscr.2013.05.016>.
3. Glaysher, M.A., Cruttenden-Wood, D. and Szentpali, K. A Rare Cause of Upper Gastrointestinal Haemorrhage: Ruptured Cystic Artery Pseudoaneurysm with Concurrent Cholecystojejunal Fistula. International Journal of Surgery Case Reports, 2014; 5: 1-4. <http://dx.doi.org/10.1016/j.ijscr.2013.11.005> [Citation Time(s):1].