

SYSTEMIC REVIEW OF IDIOPATHIC CONDYLAR RESORPTION**Amjad Nasser Alhajri* and Dr. Talal H. Bokhamseen**

Alfarabi College, Department of Dentistry, Riyadh, Saudi Arabia.

Article Received on
25 July 2018,Revised on 15 August 2018,
Accepted on 04 Sept. 2018

DOI: 10.20959/wjpr201817-13349

Corresponding Author*Amjad Nasser Alhajri**Alfarabi College, Department
of Dentistry, Riyadh, Saudi
Arabia.**ABSTRACT**

The previous studies and the case reports of Idiopathic condylar resorption categorized this disease as progressive and extensive in terms of condylar resorption. The idiopathic condylar resorption can be diagnosed by suitable exclusion of known causes, knowing the patient history, imaging and clinical findings. The pathogenesis of Idiopathic Condylar Resorption is still unknown. More than 75% of the Idiopathic Condylar Resorption patient's show symptoms like temporomandibular joint dysfunction (TMD) pain or discomfort, bilateral masticatory muscle and fatigue. The main aim of the study is to do systematic review all the online literatures related to Idiopathic

Condylar Resorption. This study is done to provide information and details on the current state of knowledge about ICR and limitations with the previous studies and to determine the crucial gaps in knowledge and fill in with future studies. All the studies that full filled the inclusion criteria were included in the study. Data was extracted from the online databases like Medline and PubMed Central, and tabulated. The current literature on idiopathic condylar resorption lack in the randomized clinical trials on human and also the prospective studies. The limitations of this systematic review of the literature of Idiopathic Condylar Resorption lacked the meta-analysis.

KEYWORDS: Idiopathic Condylar Resorption (ICR), temporomandibular joint dysfunction (TMD), progressive condylar resorption.

INTRODUCTION

The Idiopathic Condylar Resorption (ICR) is also referred as idiopathic condylar resorption or condylar atrophy or progressive condylar resorption or aggressive condylar resorption or cheer-leader syndrome. Idiopathic condylar resorption is used as a diagnosis of exclusion when all other diagnostics are ruled-out. Phillips and Bell reported a case of condylar

resorption following sagittal split osteotomy (SSO). Philips and Bell guessed that an alteration in the biomechanical forces due to an increase in the muscular tension can lead to Idiopathic Condylar Resorption. Idiopathic Condylar Resorption may occur following a surgery or may occur even prior to a history of surgery. Crawford et al. reported 7 cases of idiopathic condylar resorption.^[1,2]

Amett et al. speculated that dysfunctional remodeling of condyle occur due to decreased patient adaptive capacity or increased mechanical stress and forces.^[3] The researchers proposed that they are three main category of factors that cause the condyle resorption: Systemic factors, Age and Hormonal factors.^[4] The previous studies and the case reports of Idiopathic condylar resorption categorized this disease as progressive and extensive in terms of condylar resorption. That are not credited to any pathological conditions. The idiopathic condylar resorption can be diagnosed by suitable exclusion of known causes, knowing the patient history, imaging and clinical findings. The pathogenesis of Idiopathic Condylar Resorption is still unknown. The clinical manifestation of Idiopathic Condylar Resorption has been exclusively detailed by the previous researchers.

Typically Idiopathic condylar Resorption is diagnosed using the conventional two dimensional procedures like panoramic or lateral cephalometric projections.^[5] These techniques often describe the Idiopathic Condylar Resorption as a loss in the volume of condyle. The Fulcrum teeth wear, if the condyle collapses faster. This will result in the teeth that are towards the fulcrum become non-occluding. If the Idiopathic condylar resorption is less rapid, the anterior disclusion will proceed slowly. The bilateral anterior open bite starts to develop when the Idiopathic condylar resorption is bilateral.^[6] The duration of start of the idiopathic condylar resorption can be known by evaluating the degree of occlusal wear on the non-occluding teeth.^[7]

The existence of mamelons shows that ICR had initiated before or after the eruption of permanent incisors.^[8] The other reasons may be tongue thrust or thumb sucking or pacifier sucking habit or pre-existing occlusion. With the idiopathic condylar resorption, the jaw exhibits decreased vertical ramus height, posterior facial height, and the mandibular plane angle is consistently high/steep and anterior open bite.^[9] More than 75% of the Idiopathic Condylar Resorption patient's show symptoms like temporomandibular joint dysfunction (TMD) pain or discomfort, bilateral masticatory muscle and fatigue.^[10] The Idiopathic Condylar Resorption is diagnosed using magnetic resonance imaging (MRI) that shows

diminished volume of the condyle. The resorption may occur in the superior side, antero-superior and all other surfaces of the condylar head. In few cases, the condylar surface is round in shape even after diminished volume and height.^[11]

AIM AND OBJECTIVE

The main aim of the study is to do systematic review all the online literatures related to Idiopathic Condylar Resorption.

1. To collate and critically evaluate the literatures of Idiopathic Condylar Resorption.
2. To understand the physiopathology of the disease.
3. To determine the mechanism of the Idiopathic Condylar Resorption.
4. To evaluate about the surgical and non-surgical risk factors on evidence based medicine base of Idiopathic Condylar Resorption.

RATIONALE BEHIND THIS STUDY

The rationale behind the systematic review of Idiopathic Condylar Resorption is to provide information and details on the current state of knowledge about ICR and limitations with the previous studies and to determine the crucial gaps in knowledge and fill in with future studies.

MATERIALS AND METHODS

Search Design

To perform the systematic search using the Medline and PubMed Central in the English language with the aim to review the literature related to the Idiopathic Condylar Resorption.

Search Terms Used

The search terms that were used to review the literature are: “condylar resorption” OR “progressive condylar resorption” OR “idiopathic condylar resorption” OR “condylar atrophy” OR “condylitis” ‘idiopathic AND condylar AND resorption’, ‘progressive AND condylar AND resorption’, and ‘aggressive AND condylar AND resorption’.

Filters

Initially no filters were applied to search, to make sure that all the previous studies are available for successive screening. Nevertheless, while applying the exclusion criteria, the filters were added to the Medline and PubMed Central, like: Human studies, studies in

English language, adults of 18 years and old. These filters aids to ease the exclusion of the studies from the original list of literatures.

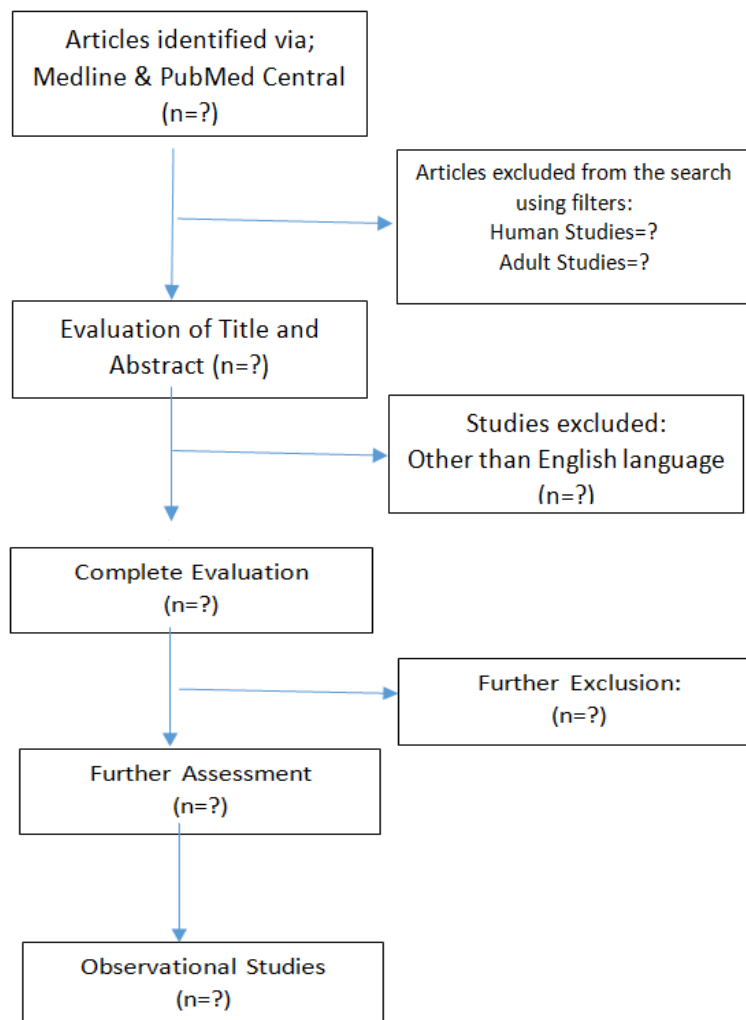
Inclusion Criteria

Articles with full text in English language, studies based on human, randomized study, prospective study, comparative articles, primary cases of Idiopathic Condylar Resorption and various case series.

Exclusion Criteria

The previous literature reviews, case reports, previous descriptive studies, the opinion articles, review about the systemic diseases related to Condylar Resorption, case reports of re-operation of Idiopathic Condylar resorption.

All the abstracts were reviewed by only one observer. All the studies that full filled the inclusion criteria were included in the study. All the articles and case studies were studied and analyzed. This was followed by a series of research of the references associated with the Idiopathic Condylar Resorption. Depending on the exclusion criteria the studies were excluded from the study. The studies included were studied, reviewed and analyzed by the principal investigator.

Flow Chart Showing the systematic review after applying the inclusion and exclusion criteria**DATA EXTRACTION**

The original list of all the full-text articles were screened using the inclusion and the exclusion criteria and was closely assessed. Data was extracted from the online databases like Medline and PubMed Central, and tabulated.

RESULTS

Extracted data from Medline and PubMed Central is to be entered in the tables created by Principal Investigator. The outcome will be observed and the results are recorded. Each article selected for the study is closely reviewed and the data entered in the predesigned tables are evaluated and handled by the principal investigator. Out of the total articles found on the databases, the duplicates were removed. About 185 articles were found relevant to our study. The titles and abstracts of these articles were studied to evaluate the articles based on

the inclusion and the exclusion criteria. About 32 articles were found to be compatibles with our criteria. If the case series /articles that did not provide correct and complete information about the study related to Idiopathic Condylar Resorption, were removed. Finally 11 full articles were selected for the extraction of the data that full-filled the inclusion and the exclusion criteria. All these articles were included our systematic review of the literature related to Idiopathic Condylar Resorption.

Author	Year Of study	Study Title	Study	Result/ Treatment
Mehra P, Nadershah M, Chigurupati R	2016	Is alloplastic temporomandibular joint reconstruction a viable option in the surgical management of adult patients with idiopathic condylar resorption?	A retrospective analysis of patients with ICR managed by bilateral total TMJ replacement and concomitant mandibular advancement with or without maxillary surgery was performed using data gathered from medical records.	The primary treatment outcomes of interest were 1) correction of anterior open bite malocclusion, 2) mandibular advancement, and 3) Increase in posterior facial height.
Sansare K, Raghav M, Mallya SM, Karjodkar F.	2015	Management-related outcomes and radiographic findings of idiopathic condylar resorption	Studies that identified patients as having either ICR or progressive condylar resorption were analyzed	Treatments included occlusal splints with orthodontic treatment, condylectomy with costochondral graft, and other surgical approaches.
Kobayashi T, Izumi N, Kojima T, Sakagami N, Saito I, Saito C.	2012	Progressive condylar resorption after mandibular advancement.	Progressive condylar resorption is an irreversible complication and a factor in the development of late skeletal relapse after orthognathic surgery.	The mandible should therefore be advanced only when the condyles are stable on radiographs, and careful attention should be paid to postoperative mechanical loading on the TMJ in high-risk patients.
Troulis MJ, Tayebaty FT, Papadaki M, Williams WB, Kaban LB.	2008	Condylectomy and costochondral graft reconstruction for treatment of active idiopathic condylar resorption.	Patients with an identifiable cause of condylar resorption such as rheumatoid or degenerative arthritis, trauma, or steroid use	This study indicate that a stable and satisfactory outcome is achievable in patients with active idiopathic condylar resorption treated by condylectomy and CCG reconstruction.
Hwang SJ, Haers PE, Seifert B, Sailer HF.	2004	Non-surgical risk factors for condylar resorption after orthognathic surgery.	To study that Condylar resorption following orthognathic surgery is an important cause of late skeletal relapse.	Posteriorly inclined condylar neck should be considered as a relevant non-surgical risk factor.
Borstlap WA,	2004	Stabilization of sagittal	Condylar Morphology	The occurrence of pain

Stoelinga PJ, Hoppenreijts TJ, van't Hof MA.		split advancement osteotomies with miniplates: A prospective, multicenter study with two-year follow-up. Part III – Condylar remodeling and resorption	Scale (CMS), analyze radiological changes in the TMJ after BSSO in relation to postoperative relapse	and TMJ sounds in the first few months postoperatively are highly suspicious for condylar changes to occur in the next months.
Wolford LM.	2001	Idiopathic condylar resorption of the temporomandibular joint in teenage girls (cheerleaders syndrome)	Patients predisposed to ICR are usually teenage girls in their pubertal growth phase; they typically have high occlusal plane angle facial types and class II skeletal and occlusal relationships were studied.	ICR can be treated very effectively with the specific treatment protocol described here, provided the articular discs and condyles are still salvageable.
Wolford LM, Cardenas L.	1999	Idiopathic condylar resorption: Diagnosis, treatment protocol, and outcomes.	Imaging that usually demonstrates small resorbing condyles and TMJ articular disk dislocations were studied.	A specific treatment protocol has been developed to treat this condition that includes: (1) removal of hyperplastic synovial and bilaminar tissue; (2) disk repositioning and ligament repair; and (3) indicated orthognathic surgery to correct the functional and esthetic facial deformity.
Huang YL, Pogrel MA, Kaban LB.	1997	Diagnosis and management of condylar resorption.	Investigation included serial clinical examination, lateral cephalograms, tomograms, and a technetium isotope bone scan when indicated.	Condylectomy and costochondral grafting appeared to produce stable and functional results.
De Clercq CA, Neyt LF, Mommaerts MY, Abeloos JV, De Mot BM.	1994	Condylar resorption in orthognathic surgery: A retrospective study.	Examined for shortening of the ascending ramus of the mandible because of condylar resorption.	There was no correlation between resorption and age, the amount of retrognathism, or the presence of preoperative temporomandibular joint dysfunction.
Moore KE, Gooris PJ, Stoelinga PJ.	1991	The contributing role of condylar resorption to skeletal relapse following mandibular advancement surgery: Report of five cases.	Preoperative factors that may contribute to the development of condylar resorption	A target group is defined in which special considerations should be made with regard to preoperative and postoperative management.

DISCUSSION

The result of this systematic review of literatures related to Idiopathic Condylar Resorption showed that most of the studies had instigated from a restricted number of research types. Most of the studies were the case series of Idiopathic condylar resorption and with a few randomized clinical trials. Idiopathic Condylar Resorption is a progressive type of resorption with unidentified etiology. The systematic review showed that the Idiopathic Condylar Resorption diagnosis is poor and not very accurate in the literatures. The management of ICR is controversial as seen the literatures among the surgeons. There is a lack of randomized clinical trials and prospective studies related to idiopathic condylar resorption in the previous studies.

The number of articles related to idiopathic condylar resorption included in this study was reduced due to the inclusion and exclusion criteria. All the selected articles were carefully reviewed. The filters were also added to the search, like articles in only English language, study on human, studies on adults above 18 years. Upon application of the filters, inclusion and exclusion criteria, only 11 studies were left that were assessed. Our studies included the study about the Author's name, Year of Research, study title, study description and the results or treatment suggested for the idiopathic condylar resorption. All the studies selected were from the time period between 1991 till 2017.

Thus from this study we can assess that very poor research has been done on the diagnosis of idiopathic condylar resorption and also its treatment. The current literature on idiopathic condylar resorption lack in the randomized clinical trials on human and also the prospective studies. There is a need for future research in this field to carry out the clinical trials on human and also to carry on prospective studies and determine the correct diagnostic process and also the updated treatment guidelines for idiopathic condylar resorption.

LIMITATIONS

The limitations of this systematic review of the literature of Idiopathic Condylar Resorption lacked the meta-analysis, as the articles included in this study were with less evidence and not likely to carry on the meta-analysis.

CONCLUSION

This systematic review has determined a significant urgency to carry-on further research in the field on idiopathic condylar resorption. There is very less articles available for the study

in English language. The studies on idiopathic condylar resorption should focus on advanced planning of treatment and prognosis. This study also assessed the need to document the outcomes reported in the non-surgical managing of Idiopathic Condylar Resorption. There is also a need for the studies that have long follow ups to overcome the complications related to the Idiopathic Condylar Resorption. More studies associated to the multi-center, prospective studies and randomized clinical trials will help us to evaluate the treatment outcomes of Idiopathic Condylar Resorption and also minimize the potential bias.

ETHICAL CONSIDERATIONS

Compliance with ethical standards

Ethical approval: This proposal does not contain any studies with human participants performed by any of the authors.

Conflict of interest: The authors do not have any commercial associations that might pose or create a conflict of interest with information presented in this communication. No intramural or extramural funding supported any aspect of this work.

REFERENCES

1. Sansare K, Raghav M, Mallya SM, Karjodkar F. Management-related outcomes and radiographic findings of idiopathic condylar resorption: A systematic review. *Int J Oral Maxillofac Surg*, 2015; 44: 209–16.
2. Wolford LM, Cardenas L. Idiopathic condylar resorption: Diagnosis, treatment protocol, and outcomes. *Am J Orthod Dentofacial Orthop*, 1999; 116: 667–77.
3. Wolford LM. Idiopathic condylar resorption of the temporomandibular joint in teenage girls (cheerleaders syndrome) *Proc (Bayl Univ Med Cent)*, 2001; 14: 246–52.
4. Mehra P, Nadershah M, Chigurupati R. Is alloplastic temporomandibular joint reconstruction a viable option in the surgical management of adult patients with idiopathic condylar resorption? *J Oral Maxillofac Surg*, 2016; 74: 2044–54.
5. Hwang SJ, Haers PE, Seifert B, Sailer HF. Non-surgical risk factors for condylar resorption after orthognathic surgery. *J Craniomaxillofac Surg*, 2004; 32: 103–11.
6. Moore KE, Gooris PJ, Stoelinga PJ. The contributing role of condylar resorption to skeletal relapse following mandibular advancement surgery: Report of five cases. *J Oral Maxillofac Surg*, 1991; 49: 448–60.

7. Wohlwender I, Daake G, Weingart D, Brandstätter A, Kessler P, Lethaus B. Condylar resorption and functional outcome after unilateral sagittal split osteotomy. *Oral Surg Oral Med Oral Pathol Oral Radiol Endod*, 2011; 112: 315–21.
8. Huang YL, Pogrel MA, Kaban LB. Diagnosis and management of condylar resorption. *J Oral Maxillofac Surg*, 1997; 55: 114–9.
9. Ahmad M, Hollender L, Anderson Q, Kartha K, Ohrbach R, Truelove EL, et al. Research diagnostic criteria for temporomandibular disorders (RDC/TMD): Development of image analysis criteria and examiner reliability for image analysis. *Oral Surg Oral Med Oral Pathol Oral Radiol Endod*, 2009; 107: 844–60.
10. Jordan A, McDonagh JE. Juvenile idiopathic arthritis: The pediatric perspective. *Pediatr Radiol*, 2006; 36: 734–42.
11. Patel A, Moles D, O’Neil J, Noar J. Digit sucking in children resident in Kettering (UK) *J Orthod*, 2008; 35: 255–61.
12. Crawford JG, Stoelinga PJ, Blijdorp PA, Brouns JJ. Stability after reoperation for progressive condylar resorption after orthognathic surgery: Report of seven cases. *J Oral Maxillofac Surg*, 1994; 52: 460–6.
13. Fjeld M, Arvidsson L, Smith HJ, Flatø B, Ogaard B, Larheim T. Relationship between disease course in the temporomandibular joints and mandibular growth rotation in patients with juvenile idiopathic arthritis followed from childhood to adulthood. *Pediatr Rheumatol Online J*, 2010; 8: 13.
14. Müller L, Kellenberger CJ, Cannizzaro E, Ettlin D, Schraner T, Bolt IB, et al. Early diagnosis of temporomandibular joint involvement in juvenile idiopathic arthritis: A pilot study comparing clinical examination and ultrasound to magnetic resonance imaging. *Rheumatology (Oxford)*, 2009; 48: 680–5.
15. Cannizzaro E, Schroeder S, Müller LM, Kellenberger CJ, Saurenmann RK. Temporomandibular joint involvement in children with juvenile idiopathic arthritis. *J Rheumatol*, 2011; 38: 510–5.