

## MANAGEMENT OF DADRU KUSHTHA: A CASE STUDY

Pooja G. Pantawane\*<sup>1</sup> and Dr. Pradnya S. Swan<sup>2</sup>

<sup>1</sup>PG Scholar, Dept. of Rasshastra & Bhaishajya Kalpna, Government Ayurved College & Hospital, Nagpur Maharashtra.

<sup>2</sup>Associate Professor, Dept. of Rasshastra & Bhaishajya Kalpna, Government Ayurved College & Hospital, Nagpur Maharashtra.

Article Received on  
21 Feb. 2020,

Revised on 11 March 2020,  
Accepted on 01 April 2020,  
DOI: 10.20959/wjpr20204-17183

**\*Corresponding Author****Pooja G. Pantawane**

PG Scholar, Dept. of  
Rasshastra & Bhaishajya  
Kalpna, Government  
Ayurved College &  
Hospital, Nagpur  
Maharashtra.

**ABSTRACT**

**Background of the study:** skin is a primary external covering of body mostly affected by fungal infections. In Ayurveda skin fungal infection is termed as kushtha & it is clinically similar with the symptoms of tinea corporis. Aacharya sushruta & vagbhata included it under mahakushtha & aacharya charak has explained it under kshudra kushtha. **Aim:** To study the role of krumihar chikitsa and shaman chikitsa in tinea versicolor. **Objective:** 1. To understand concept of dadru kushtha. 2. To observe the effect of krumihar chikitsa and shaman chikitsa in present study. **Methodology:** In present case study 25 yr old male patient in skin opd of govt. ayurved hospital, Nagpur, having symptoms of 2-3 white patches on left side of back, large skin colour patch on right side of upp back & 3-4 white patches on rt side of

chest with itching since 1 & 1/2 yr. which can be correlate with tinea versicolor acc to modern. Pt is treated with deepan pachan, krumihar and shaman chikitsa respectively.

**Discussion:** In this case shaman chikitsa given leading to decrease in symptoms of patient.

**Conclusion:** Treated with krumihar & shaman chikitsa; a good relief was observed in the patient. Details of which will be presented in complete paper & at the time of presentation.

**KEYWORDS:** Dadru kushta, tinea corporis, tinea versicolor.

**INTRODUCTION**

Skin is the largest organ of body, plays a chief role in maintaining barrier between internal and external environment. it is just like mirror reflection & manifesting various type of inner abnormality or diseased condition.<sup>[1]</sup> as skin is a primary external covering of body it is

mostly affected by fungal infections which is one of the most common skin disease. According to WHO prevalence rate of superficial mycotic infection is 20-25%.<sup>[2]</sup> In Ayurveda skin fungal infection is termed as kushtha & it is clinically similar with the symptoms of tinea corporis.

Aacharya sushruta & vagbhata<sup>[3]</sup> included it under mahakushtha & aacharya charak has explained it under kshudra kushtha.<sup>[4]</sup> aacharya sushrut has described dadru as kapha Pradhan vyadhi and aacharya charaka described is as pitta-kapha Pradhan dosha.

In Ayurveda there are some causative factor for kushth like intake of incompatible & contaminated food, suppression of natural urges, drinking cold or chilled water just after exposure to sunlight or after doing physical work, day time sleep, excessive intake of salty or acidic food items etc.<sup>[11]</sup>

According to modern, tinea corporis is a fungal infection which may occurs on any part of the body. It having the symptoms of- ring like appearance or circular in shaped, rashes are itchy, rings that multiply and merge together and may develop blisters & pus filled sores near the ring. Tinea has different types according to present in different body parts. i.e tinea pedis, tinea cruris, tinea corporis, tinea unguis, tinea versicolor, etc.

The present case study is of dadru which we can correlate with tinea versicolor (also called as pityriasis versicolours). This title designates a superficial fungal infection that changes colour. causative organism is *Malassezia furfur* now called as *pityrosporum orbiculare*.<sup>[5]</sup> it is having symptoms like

- patches that may be white, pink, red or brown and can be lighter or darker than the skin around them.
- numerous scaly patches on the upper chest & back, proximal arms, neck, etc.
- the lesion may be hypopigmented (depending on skin colour).
- it may change the colour of lesions.

Causative factor for this is hot, humid weather, oily skin, hormonal changes, weakened immune system.<sup>[6]</sup>

## CASE STUDY

A 25 yr old male patient came to Govt. Ayurved Hospital, Nagpur with complaints of

- Large Skin/ redish colour patch with elevated border on rt side of upp. Back

- 3-4 White colour patches on rt side of chest
- Severe itching at site
- Aggravation of itching during night.

Patient was suffering from the above complaints since 1 & 1/2 yr, patient was having irregular bowel evacuation & loss of appetite, he consulted allopathic dermatologist & was prescribed some medicine orally and topically but there was no significant relief.

Opd no. – 58108

### Past history

- No H/O – DM, HTN, TB, no any major operative
- F/H – no any skin disorder.

Aahar – intake of nonvegetarian food, oily & junk food.

Vyasan- no any addiction.

Vihara- travelling 2-3 times in month, work in AC room.

On examination(ashtvidh parikshan)

Mala- asamyak                      kshudha- kshudhamandya

Mutra- praakrut                      nidra- prakrut

Jivha- saam                      naadi- vaatpittaj 84/min

BP- 130/82 mmhg

### Diagnosis

- primary patient was diagnosed as Krumi.
- secondary diagnosed as Dadru (i.e Tinea versicolour)

### Samprapti ghatak

Dosha- kaph Pradhan

Dushya- Ras, Rakt, Maans, Ambu

Strotas- Raktvaha strotas

Udhbhavsthan- Aamashay

Vyaktisthaan- urah Pradesh, udar Pradesh

## Management

When patient came to Govt. Ayurved hospital Nagpur, deepan paachan chikitsa is given upto achivement of niram lakshana which took 5 days. For this sanjivani vati 2BD, & triphala churna+vidanga churna+mushta churna 5gm BD in a day was given.

Then after 5 days krimihar chikitsa was given to patient. For this, tab Albendazole 400mg-1 hs, vidangarishta-3tsp, krumikuthar ras -2BD in a day given orally & cutis ointment was given tropically.

## Treatment- 30/8/19

Sr. no	Treatment	doses	Lakshanas
1.	<i>Sanjivani vati</i>	2-0-2	Large Skin colour patch on rt side of upp back.
2.	Triphala+vidang+mushta churna	5gm-0-5gm	2-3 white patche on rt side if chest
3.	Cutis ointment	Local application	Itching at site.
			Itching aggravates at night.

## Follow up

Sr. no	Medicine	Observation of lakshanas
1 <sup>st</sup> follow up	Vidangarishta Krumikuthar ras Aarogyavardhini vati	- large skin colour patch with elevated border on rt side of upp back + -4 white patche on rt side if chest ++ - 4 white patches on lft side of upp back+++ -itching at site +++ -mala- prakrut
2 <sup>nd</sup> follow up	Tab skin all Shatavari+guduchi+aswagandha churna Cutis ointment -LA Aaragwadha+chakramarda churna – LA in takra(buttermilk)	-skin colour patch on left side of upp back convert into white colour +++ -4 white patche on rt side if chest +++ -4 white patches on lft side of upp back+++ -itching at site +++ -itching at site- totally absent
3 <sup>rd</sup> follow up	Tab skin all Mahamnjishtadi kwath Shatavari+guduchi+aswagandha churna Aaragwadha+chakramarda churna – LA in takra(buttermilk)	-large white colour patch on upp back faded again to skin colour + -white patches on rt side of chest is almost diminished + - 1 patch among the 4 patches on lft side of upp back completely diminished and 3 patches get faded. - itching - absent

## DISCUSSION

In present study krimihar chikitsa plays very important role, to reduce kandu of patient where shaman chikitsa plays important role in decreasing hypopigmentation and control the frequency of spreading of white patches on skin.

**1. Aarogyavardhini vati<sup>[7]</sup>**

Main contains are kajjali, loha bhasma, abhrak bhasma, shilajit, triphala, chitrak, kutaki, nimba patra & trikatu churna etc. with bhavana dravya of nimbkwath. Here most of herbal drugs are tikta rasatmaka, where as bhasma i.e abhraka bhasma etc carry these drug to sukshma level. act as raktpachak, nimba is kandughna in property and chopchini is having krumihar property.

**2. Krumikuthar ras<sup>[8]</sup>**

Contains karpoor, indrajav, traayaman, ajmoda, vaavding, hingul, vatsnabh, naagkeshar, with bhavana of bhrungraj, palashbeej and undirkaani swaras. Karpoor & vaavding in this work as krumighna, indrajav work as yakrutottejak, pittarechak & saarak, hingul also work as jantughna, rasayan and yogvahi.

**3. Vidangarishta<sup>[9]</sup>**

Contains vidanga, pippali, kutajtwak, paatha, aamalaki, dhataki, rasna, indrajav, elavaluka, madhu etc. vidangarishta expel out krumi from abdomen & retains the further growth of krumi.

**4. Chakramarda, aaragwadha lepa**

Is well known kushtaghna, kandughna, dadrughna & kaphvathar property.

**5. Cutis ointment**

Cutis ointment of vasu pharma Contain mahamarichyadi tail, neem oil, karanj oil, karpoor, lemongrass oil, shuddha gandhak, shu. Tankan, & tutha.

**6. Mahamnjishthadi kwath<sup>[10]</sup>**

It contains manjishtha, mushta, kutaj, guduchi, nagar, kushta, bharangi, vacha, nimb, haridra, triphala, trayamaan, chitrak, vidanga, shatavari, vasa, pathya, varun, bakuchi, karanj, Ananta, sariva etc. it is raktshodhak, twachya, kushtaghna, and raktgaami, it has effective raktprasadan action.

**7. Skin all Tablet**

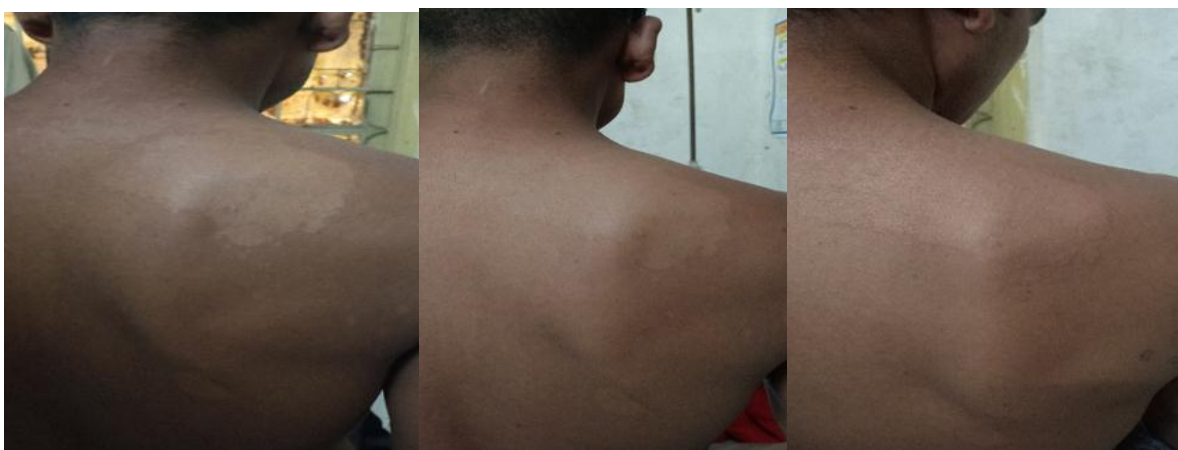Skin all tablet are of vasu pharma which contain neem patra ghan, neemchaal ghan, manjishtha ghan, saariva ghan, kutaki ghan, guduchi ghan, chopchini & bhavana of neemptra and guduchi kwath. Where sariva and manjishta is varnya dravya, sariva is also act as raktpachak, nimba is kandughna in property and chopchini is having krumihar.

**8. Shatavari+Guduchi+Ashwagandha churna<sup>[12]</sup>**

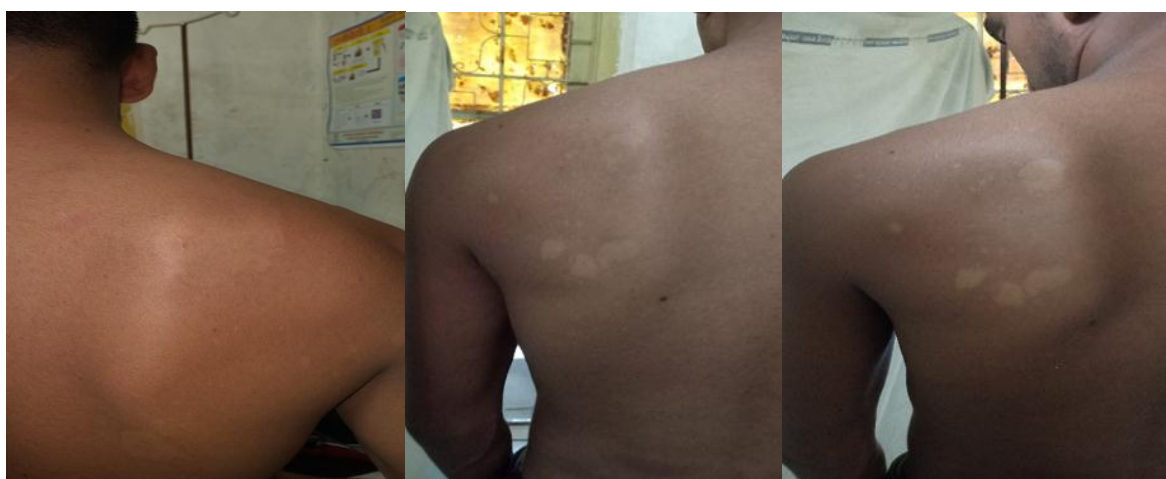Shatavari is Madhur vipaki, shita viryatmak. Its is balya, agnivrdhak & vayssthapan. Aswagandha is kashay rasatmak, balakaarak, rasayan, & switra kushtahar. Guduchi is rasayani, balya, krimighna.

**OBSERVATIONS**

1. After treatment Large white patch on rt side of upp back get fainted & elevated border of patch get diminished. And control frequency of spreading of patch.
2. On lft side of upp back was having 4 medium size of white patches, among them upper 1 patch get completely diminished while other get fainted.
3. Patches of rt side of chest get fainted.



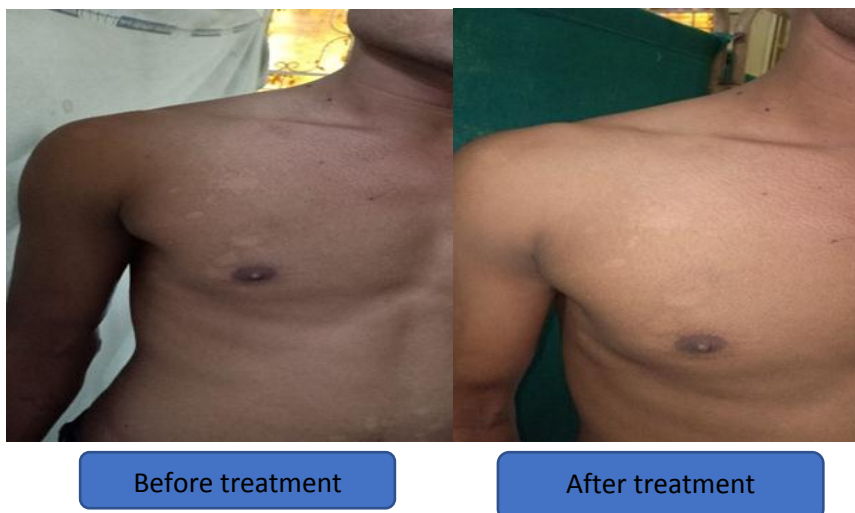
Before treatment

At 2<sup>nd</sup> follow upAt 3<sup>rd</sup> follow up

After treatment

Before treatment

After treatment



## CONCLUSION

In present case depending on lakshanas it was diagnosed as Dadru kushtha. This case study is documented evidence for successful management of dadru, here krimihar chikitsa reduces kandu of patient where as saman chikitsa plays important role to reduce Shweta varana mandala of patient. This is one among the relapsing type of skin disease so patient was advised to follow pathyapathya like aahar, vihar etc.

## REFERENCES

1. ISSN:2327-5162 <https://www.omicsonline.org>>proceedings
2. WHO, 2005. Epidemiology & management of skin diseases in children in developing countries WHO, Geneva WHO/FCHCAH/05.12.
3. Vagbhata, Ashtang Hridaya, Edited by Harishastri paradakara Vaidya, published by Choukhamba prakashan, Varanasi; Reprint, 2018; 14/7-10: 524.
4. Agnivesha: Charak Samhita, Edited by Yadavaji trikamaji, published by Choukhamba publication, Varanasi, 2017; 7/30: 451.
5. <https://www.medicinenet.com>
6. <https://www.webmd.com>>
7. Ras Ratna Samucchaya, Ambika Datt Shastri, Chaukhamba amarbharti prakashan, Varanasi, reprint, 2015; 436.
8. Nighantu Ratnakar, edited by shri Dattaram Mathur, published by Khemaraj shrikrushna parakashan, 2017; krumirogchikitsa pg no. 57.
9. Sharandhar Samhita, Edited by Bhramhanand Tripathi, chaukhamba surbharati prakashan, Varanasi, 2017; 10/49-54.



10. Sharandhar Samhita, Edited by Bhramhanand Tripathi, chaukhamba surbharati prakashan, Varanasi, 2017; 2/137-142.
11. Charak Samhita, Vaidyamanorama Hindi commentary, Acharya Vidyadhar Shukla & Prof. Ravidatta Tripathi. Chaukhamba Surbharati Prakashan, Chikitsa Shtan. Kushtha Chikitsa Adhyay, shloka no. 4.
12. Bhavprakash Nighantu, Commentary by Prof. K.C. Chuneekar, Edited by Dr. G.S. Pandey: 2010; pg no, 379, 258, 378.