

A CASE STUDY OF FACIAL HIRSUTISM (AVANCHITA ROMA) BY AYURVEDIC TREATMENT

Dr. Sujata Gopalkrishna^{1*} and Dr. Vinod Jadhav²

¹PG Scholar, Department of PG Studies in Shalakyatantra, Svmamc, Ilkal.

²Professor, Guide & HOD, Department of PG Studies in Shalaky Tantra, Svmamc, Ilkal.

Article Received on
30 Jan. 2021,

Revised on 20 Feb. 2021,
Accepted on 12 Mar. 2021

DOI: 10.20959/wjpr20214-20107

***Corresponding Author**

Dr. Sujata Gopalkrishna

PG Scholar, Department of
PG Studies in
Shalakyatantra, Svmamc,
Ilkal.

ABSTRACT

One's appearance bespeaks dignity and depth of his character, is generally what modern world has defined beauty as. Appearance has become an important aspect in exhibiting self confidence. And so cosmetology has become an important field. Unwanted hair (hirsutism) present in body causes cosmetological as well as psychological problems to individuals. Such patients even experience rejection due to social stigma, specially women and at times opt for expensive cosmetic therapies which drain them financially. The reason for hirsutism can be of unknown origin or can be secondary to underlying illness. Nowadays many depilation techniques are available like plucking, threading, shaving, waxing, electrolysis, laser therapy

etc. These can have sometimes complications to patients, sometimes reoccurrence of hair is seen making it temporary result oriented and some are highly expensive for a common man to afford. In this article, we have presented a case having hirsutism at neck region. Treatment taken was lomshatana lepa (hartala, shankh, sarjakshara & manashila) externally. And internal medicines were given for underlying shaulya condition along with diet and lifestyle management. Classical formulation is taken which is easily available, cost effective and having fewer side effects to treat this condition.

KEYWORDS: Avanchita roma, Atiloma, Facial hirsutism, Lomashatan lepa.

INTRODUCTION

In Ayurveda, Atilomatā is explained in Aṣṭau ninditīya adhyāya of *Caraka Saṃhitā* as a separate entity.^[1]

Atilomatā is more elaborated word used in ayurveda which includes both male and female having excess or unwanted hair growth at different parts of body.

Atilomatā condition can be considered as the hirsutism which is defined as excessive body hair in men and women on parts of the body where hair is normally absent or minimal.^[2] which is a psychosomatic disease. Hirsutism gives the inferences of endocrinal etiology for the excessive hair growth. Hair is a stratified keratinized epithelium and the hair follicle starts its development from 8-10 weeks of gestation. The facial and body hair in men is mostly of the terminal type. In males there will be naturally higher level of testosterone, but when it comes to females, considered as a pathological condition i.e., hirsutism in which the excessive hair growth over chin, face, chest, back, upper arm. This condition can be commonly noticed in cases of PCOS, metabolic syndrome associated with obesity, insulin resistance or it may be idiopathic, where normal ovulatory function with normal circulating androgen levels seen. Non-androgenic causes of hirsutism are relatively rare e.g. excess hair growth of acromegalics. In addition, hirsutism may develop with chronic skin irritation because hair is designed to protect the skin.^[4]

It affects around 5-10% of the women.^[3] This is a common presenting complaint in the Out Patient Department for cosmetic reasons.

In Ayurveda Loma (hair) is a parthiva dravya (earth element) considered to be developed from Pitruja Bhava (inherited from father) during antenatal period.^[5] According to Vagbhata of the text Ashtanga Sangraha 'Loma (hair)' develops during 6th month of intrauterine life.^[6] According to the text Charaka samhita, Loma is considered as Asthi dhatu Mala (excreta of bone tissue) and is rooted in the 6th layer of the skin.^[7] Lomshatana (depilation) medications in classical texts chiefly comprise of topical applications.

Consent

Informed consent was taken prior to case study.

Case report

A 28 year female patient visited OPD on 12/11/2019 at SVMAMC Karnataka, with chief complaints of facial hair on the chin and neck region since 1yr. Her weight was on higher side i.e.70 kg, height was 160 cm. Skin had lost luster and mild acne was seen. She had a history of delayed menarch. She was into clerical or sitting job from 4 yrs. Since her working

schedule was hectic, she had started indulging into fast food and improper timing of food. This led to her weight gain of 12 kgs in span of 4 yrs. Sometimes irregular menses was also seen. From one year she noticed hair on chin and neck (above Adams apple region) which she would manage by threading. Slowly hair started getting thicker and that area remained thick and blackish. (Eventually threading and shaving was of no help). Stress had started prevailing as this age was more about looking good and presentable. So she went to do a laser treatment, which was very expensive for her and first visit left her with rash and burning sensation of the skin. This depressed her further. For above complains she was then treated by ayurvedic medicine. Her vitals were in normal limits. In general examination her chin and neck was having thickened hair, thick and darkened skin.

Investigations

Routine hematological examination along with thyroid function and fasting sugar and PP sugar was done, which was in normal limits.

USG of abdomen and pelvis was done which had no significant abnormalities.

Treatment protocol

Medication given for 15 days

- Lomashatana lepa application on neck and chin area once in a day with water was mentioned. (After threading)
- Mahamanjistadi kashyam - 20 ml BDS morning and evening.
- Medohar guggulu 2- 2 BDS after food.
- Trifala tab 2 tablets at nights before sleep.

Advice

Aahar (diet)- Patient was mentioned to have Vegetables like guards e.g bottle guard, rich guard, snake guard, ivy guard. Carrots, beans, cabbage, green leafy vegetables etc.

Have millets like finger millet (raagi) etc and increase intake of fruits.

To Avoid Potatoes, brinjal, spicy and oily food. with excess meat eating .

Vihar (regimen) - She was mentioned: To awake in morning at brahma muhurta and practice yoga and dhyana. Not to overeat or skip meals, Avoid heavy junk food and meat in her diet. Night to sleep early.

First Follow up after 15days - Her skin looked brighter with more luster, Hair growth on chin and neck was slightly delayed, thickness and darkness persisted same. A mood fluctuation has gone down little. Same medicines were continued for 30 days.

Second follow-up after 30 days - After a month her hair growth in chin and neck had gone less and darkness of skin also was decreasing. And weight had reduced by total 2.5 kgs.

Initially patient was reluctant to do full regime but as results had started coming positive she became enthusiastic to follow all. Yoga and meditation was very helpful to get stress levels down.

The medication of 45 days with this topical application though ensures remission in complaints, has not showed complete cure. To get complete cure the topical applications was given till permanent depilation.

DISCUSSION

In Ayurveda, initial line of treatment is *nidāna parivarjana* as well as to treat accordingly by understanding the disease pathogenesis with the guidance of detailed analysis of symptoms, status of *doṣas*, *dhātus*, *agni*, and *srotas*. Hirsutism due to PCOS or obesity like conditions can be considered similar to the pathology of prameha which includes *kleda vṛddhi* along with *maṃsā*, *medha duṣṭi* manifesting in *tvak* resulting in *Atilomatā*. Obesity contributes modestly to the risk of developing PCOS and adds to pathophysiology in already affected women by aggravating degree of insulin resistance and hyperinsulinemia, so the insulin resistance can be understood as one of the leading factor in the manifestation of atilomatā (hirsutism)

Possible mode of action of the lomshatana lepa

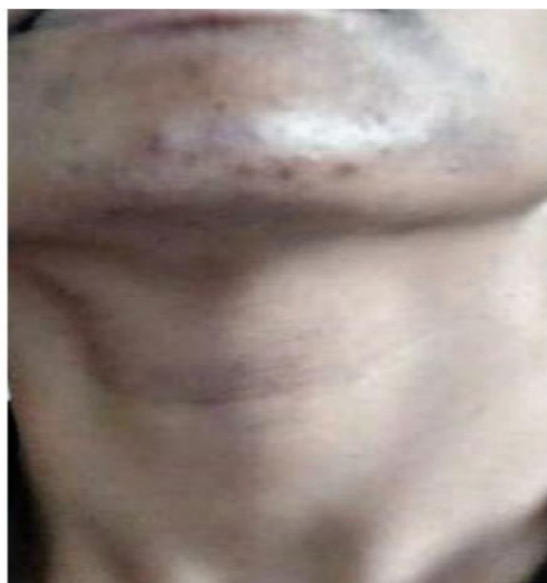The ingredients Haratala, Manashila, Sarja Kshara and Shanka Churna, does the Deepana of Bhrajaka Pitta due to Katu Rasa, Katu Vipaka, Ushna Veerya, Teekshna Guna.

Because of Sookshma, Teekshna, LaghuGuna it acts as Srotoshodhaka, thus helps in penetration of the Veerya of the Dravya into the Tvacha through Lomakupa, Leading to Swedakshaya. Furthermore, the Dravyas possess Varnya and Lekhana Karma along with the Keshaghna Karma.

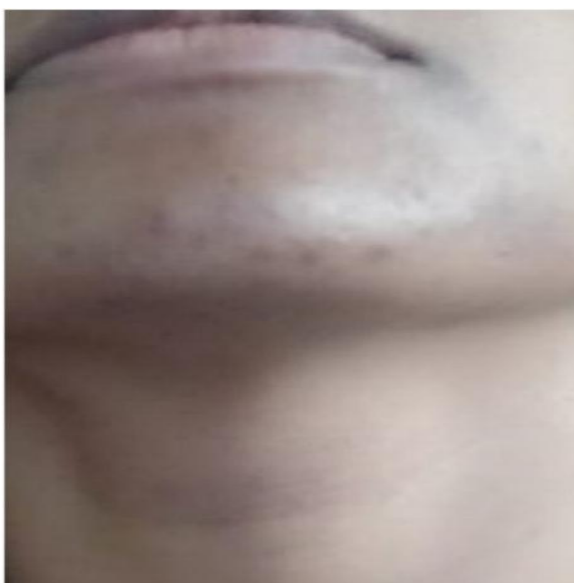
Thus, by synergistic action these drugs serve the purpose of Lomashatana.

RESULT

The remarkable change in facial hirsutism before treatment and after treatment is shown in the picture below.



BEFORE



AFTER

CONCLUSION

28 yrs female patients with facial hirsutism due to obesity in a case study was treated with topical application of Lomshatana Lepa. Internal medicines were given for underlying shaulya condition along with healthy eating habits, weight loss measures and stress management as additional measures which proved very effective. Classical formulation is taken which is easily available, cost effective and having no side effects to treat this condition. The study showed that there was statistically significant reduction in facial hair density and facial hair re-growth with no side effects. Which implies that its safe and effective in the management of facial hirsutism. When compared to depilatory electrolysis and Laser therapy. Thus, the case study suggests that Lomshatana Lepa is effective for facial hirsutism.

ACKNOWLEDGMENT

Special thanks to my Guide Dr Vinod Jhadhav, Teaching staff of Dept. of Shalakyatantra, OPD staff of SVM College of Ayurveda, ILKAL.

REFERENCES

1. Prof. P.V. Sharma, Chakrapanidatta, Charka Samhita, Chaukhamba Orientalia, edition, Chikitsasthana, Chapter, 1995; 15: 160-19.
2. Hirsute - meaning. London: Merriam Webster Dictionary. Retrieved, 2016; 10.
3. Habif T. P. Clinical Dermatology. British Library Cataloguing in publication Data, 2010; 5: 926.
4. Mcknight E. The prevalence of “hirsutism” in young women. Lancet, 1964; 1: 410–3.
5. Agnivesa, Charaka Samhita Edited by Yadavji Trikamji, Chowkhamba Surabharati Prakashan, Varanasi, Shareera Sthana, 2005; 310: 3-7.
6. Vagbhata, Ashtanga Sangraha, Edited by Shivprasad Sharma, Chowkhamba Sanskrit Series Office, Varanasi, Shareera Sthana, 2006; 278: 2-23.
7. Agnivesa, Charaka Samhita Edited by Yadavji Trikamji, Chowkhamba Surabharati Prakashan, Varanasi, Chikitsa Sthana, 2005; 515: 15-19.
8. Ācārya Vaidya Yādavji Trikamji and Narayana Ram Acharya (ed), Suśruta Saṁhitā with Dalhaṇa Nibandha Saṅgrahā, Varanasi. Chowkhamba Sanskrit Sansthan Krishnadasa Academy, Varanasi, Reprint, Nidana sthana, 1998; 3: 279.