

**MANAGEMENT OF CORNEAL FOREIGN BODY (AKSHI-SHALYA)
REMOVAL THROUGH AYURVEDA - A CASE STUDY****¹*Sudipana Sarkar, ²S. K. Hafiz Hasan**

¹Lecturer, Department of Shalaky Tantra, Belley Sankarpur Rajib Gandhi Memorial Ayurvedic, College and Hospital, North 24 Parganas, W. B., India.

²Lecturer, Department of Agad Tantra, J. B. Roy State Ayurvedic Medical College and Hospital, Kolkata, W. B., India.

Article Received on 03 April 2026,
Article Revised on 23 April 2026,
Article Published on 01 May 2026,

<https://doi.org/10.5281/zenodo.19879790>

Corresponding Author*Sudipana Sarkar**

Lecturer, Department of Shalaky Tantra, Belley Sankarpur Rajib Gandhi Memorial Ayurvedic, College and Hospital, North 24 Parganas, W. B., India.



How to cite this Article: ¹*Sudipana Sarkar, ²S. K. Hafiz Hasan. (2026). Management of Corneal Foreign Body (Akshi-Shalya) Removal Through Ayurveda - A Case Study. World Journal of Pharmaceutical Research, 15(9), 1020-1026. This work is licensed under Creative Commons Attribution 4.0 International license.

ABSTRACT

Corneal foreign bodies are one of the most common and serious eye trauma cases reaching to ophthalmologists. The cornea is the window of the eyeball through which we are able to perceive the outside world so it is simple to understand that for visual purpose it has to be transparent. In Ayurved the foreign body in the eye is called as *Akshi-shalya* and the minute foreign body is taken out to protect the cornea by ancient methods. A case of corneal foreign body which was treated by Ayurvedic medicine and procedures is being reported here as a case study. In this case study a type of foreign body was embedded in cornea of the patient and was removed by suitable methods under the help of slit lamp. Patient was given ayurvedic topical and external medicines. This case study shows that Ayurvedic procedures can be effectively used to manage the corneal foreign body.

KEYWORDS: *Akshi-shalya*, Ancient procedures, Ayurveda,

Corneal foreign body, Cornea.

INTRODUCTION

Cornea is an important structure of optical media, damage of which may cause vision loss. The cornea is an extremely delicate and sensitive structure and hence corneal foreign body

invites immediate attention. In the case of foreign body, prompt and immediate attention may avoid complications which may permanently impair the vision later. A foreign body is any abnormal substance or object that does not belong to the body (eye). The incident of foreign body in eye is more commonly occur clinical condition. The most common foreign bodies are small particle of dust, wood particles, steel, iron and other metal, which can distress the cornea. This condition is specially common among drivers and industrial built or the person who involved in occupation like labour, road work etc. Cornea is window of the eyeball, through which we are able to perceive the world, moreover cornea is a transparent watch glass like structure, it forms anterior 1/6th of the outer fibrous coat of the eyeball, refractive index of the cornea is 1.376 mm.^[1] refractive power of the cornea is above 45 diopters, which is roughly 1/4th of the total refractive power of the eye. Histologically cornea consist of 6 layers. Form anterior to posterior these are Epithelium, Bowmen's membrane, Substantia propria, Pre-Descemet's membrane, Descemet's membrane, Endothelium.^[2]

A single case study was carried out in the OPD of Shalakyatantra, belley sankarpur rajib Gandhi memorial ayurvedic college and hospital. The patient had the complaint of foreign body in the left eye with other complains of watering, redness and difficulty in blinking of eyelid, mild photophobia and pain. In classic literature, *Akshishalyalakshanas*^[3] which are explained in *Nayanabhighatpratishedhaadhyaya* can be correlated with the sign and symptoms in the corneal foreign body. So, the treatment was given accordingly by removing of the foreign body carefully by *kshoum*^[4] (sterile cotton swab stick) and then carefully managed by the following methods-*Aschyotana* with (*Triphalagruta*), and *Parishek* with (*Lodhra-Yastimadhuksheerapak*). Procedure of *Aschyotana* and *Parisheka* is described as treatment in traumatic ocular wound and other eye diseases in Ayurveda classical texts.^{[5][6]} Thus, an attempt is made to understand and manage the corneal foreign body under the light of Ayurveda.

OBJECTIVES

1. To manage the corneal foreign body through ayurvedic treatment.
2. To understand of corneal foreign body with respect to *Nayanabhighata* which mentioned in ayurvedic classics.

MATERIALS AND METHODS

Place of study- Shalakyatantra, belley sankarpur rajib Gandhi memorial ayurvedic college and hospital.

Case study-A 35 years old male patient, a labour by profession who felt foreign body sensation in his left eye, while work. He was not using protective glasses, having corneal foreign body with watering, redness, pain, mild photophobia and difficulty in blinking eyelid since last 3 hours, had chosen for the study. The case was managed by removal of corneal foreign body by instillation of 0.5% proparacaine with the help of a cotton swab stick and by the following ayurvedic techniques- *Aschyotana* (with *Triphalaghrita*), and *Parishek* (with *Lodhra-YashtimadhuKsheerpak*).

History of present illness- Patient was apparently normal before 3 hours, gradually patient felt foreign body sensation on his left eye with watering, redness, discomfort, pain, mild photophobia and difficulty in blinking eyelid. So, patient came to Shalakyatantra, belley sankarpur rajib Gandhi memorial ayurvedic college and hospital for early treatment and to get better result.

History of past illness- No history of HTN, DM

O/E

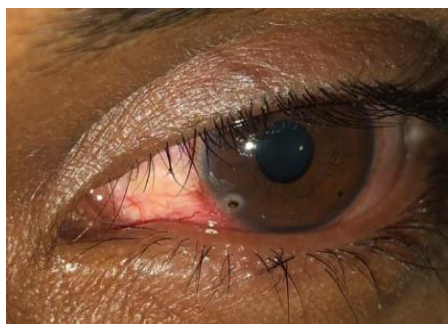On slit lamp biomicroscope examination of his left eye under topical anesthesia with 0.5% Proparacane, asuperficial foreign body was seen at 8 o'clock position of cornea, which was embedded in epithelial layer. Foreign body was removed by the following steps-

- Lids are separated by using universal eye speculum.
- An attempt to remove the foreign body by using sterile cotton swab stick (*kshoum*) was made.
- After removing the foreign body, patient was advised for procedures like "*Aschyotana*" with *TriphlaGhrita*- 12 drops (as *Ropana*)^[7], once in a day at morning for 4days followed by 10 drops for 9 days.
- "*Parisheka*" procedure with (*Lodhra -YashtimadhuKsheerpak*) – once in a day at evening, 600 *matrakala* (approximately 12 minutes) for 13 days.

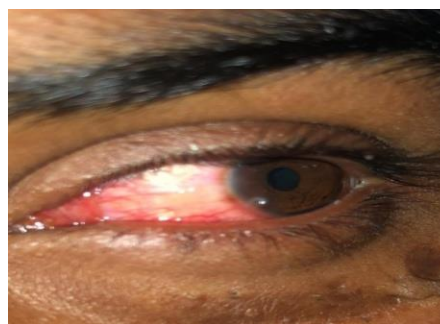
OBSERVATION

DATE	TREATMENT GIVEN	OBSERVATION
19-2-2026 to 22-2-2026	-Foreign body was removed under topical anaesthesia with 0.5% proparacaine and sterile swab stick. - <i>Aschyotana</i> with <i>TriphalaGhrita</i> 12 drops for 4 days once in a day at morning. - <i>Parishek</i> with <i>Lodhra</i> -	Foreign body sensation in left eye, congestion in bulbar conjunctiva, were mild reduced. -watering, mild photophobia, discomfort, pain, difficulty in blinking of eyelid were

	<i>YashtimadhuKsheerpaka</i> once in a day at evening 600 matrakala (approximately 12 minutes) for 4 days.	mild reduced.
23-2-2026 to 2-3-2026	- <i>Ashyotana</i> with <i>TriphlaGhrita</i> 10 drops for 9 days once in a day at morning. - <i>Parishek</i> with <i>Lodhra –Yashtimadhu Ksheerpaka</i> , once in a day at evening for 9 days	Foreign body sensation in left eye, congestion in bulbar conjunctiva, watering, photophobia, pain, discomfort, difficulty in blinking eyelid- were completely reduced



1. Day 1-Before removal of foreign body.



2. After removal of foreign body.



3. After Treatment

RESULT

The patient got relief with no complications and minimum time was taken to complete the healing of the injury.

DISCUSSION

This case study is being reported with the objective to understand the corneal foreign body with respect to “*Nayanabhighata*” which mentioned in ayurvedic classics and to show its capability in the management of some of the acute pathologies occurring in eye like corneal foreign bodies. In Classical Ayurveda texts, many techniques are described for removal of foreign body from eye, these are-

- *Parisechana*^[8]- pouring steam of water or *kashaya*
- *Adhamapana*- blowing of air
- *Parimarjana*- cleaning or removing the foreign body with piece of cotton/cloth

- *Lekhana*- scrapping is done in case of small embedded foreign particles.

But in present study the foreign body was removed under aseptic majors followed by *TriphlaGhritaAschyotana* and *Lodhra -YashtimadhuKsheerpakaParishek*. The probable mode of action of this drug are –

TriphlaGhritaAschyotana:–“*Aschyotana*” is indicated in *purvaroopaaavastha* of *netrarog*, where *toda*, *kandu*, *daha*, *raga*, *paka*, *gharshana*, and *shophare* present.^[9] In this case study patient was having the complaints of foreign body sensation, watery discharge, redness, discomfort to blinking of eyelid and mild pain. So, *TriphlaGhritaAschyotana* was given in a dose of 12 drops at morning for after removing the foreign body for 4 days followed by 10 drops at morning for 9 days. It acts as *vranaropak*. Furthermore, *ghritais* having *yogvahi*, *vat-pittashamak* and *rasayana* property.^[10] Therefore, it is the best choice of drug in ophthalmic disorders(*netraroga*). In this case, *TriphlaGhrita* having *Madhurras*, *sheetaveerya*, and *Tridoshshamak* properties.^[11] *Ghrita* is having lipophilic property which easily transports through cornea and reach to the targetcell.^[12]

Parishekwith Lodhra^[13] -*YashtimadhuKsheerpaka*:–*Lodhra*having *sheetavirya*, *chaksusya*, *sophahara* and *pittahara* properties.^[14] *Yashtimadhu* alleviates *vata* and *pitta dosha*. It is *vedanasthapaka*, *shothahara*, having *madhur rasa* and *sheetaveerya*whichmay provide soothing effect in wounds. Phytochemically, *yashtimadhuis* composed ofcumarins, triterpenoids, lignansisoflavoid, and glycyrrhetic acid etc. Which act as anti-bacterial and anti-inflammatory.^[15] *Alsokhseer*(*Cow milk*) is having *Madhurras*, *sheetaverya*, which alleviate the *vata*, *pitta*, and *raktadosha* and it is also *vedanasthapaka* and *chakshusya*.^[16] Chemically lactoferrin, lactoperoxidase which are present in*ksheer*(*Cow milk*)act as antimicrobial and very much helpful to relieving the symptoms, so it canact as wound healer.^[17]

CONCLUSION

Acharya *Sushruta* described about *Nayanaabhighatpratishedha* which deals with the traumatic ocular injury, wasmore common in old days and even today. Healso had explained about many ayurvedic techniques to manage the *abhighatajvrana* of *netra*. In this study the sterile swab stick was used to remove the corneal foreign body which is already mentioned in Ayurvedic classical text as *kshouma*. After removing the foreign body, *TriphalaGhrita* as *Aschyotana* and *Lodhra- YashtimadhuKsheerpak* for *Parishek*were applied to minimize the

sign and symptoms of *akshishalya*(Corneal foreign body). The drugs, used here, are having the properties like *vranaropak*, *chakshusya* and *vednasthapak*, *madhuraras*, *sheetaveerya*. Subsequently, the patient gets complete relief by abovementioned treatment as described in Ayurveda classics.

REFERENCES

1. AK Khurana, Comprehensive Ophthalmology, 7th edition, Jaypee Brothers Medical Publishers (P) Ltd, New Delhi, 2019; 99.
2. AK Khurana, Comprehensive Ophthalmology, 7th edition, Jaypee Brothers Medical Publishers (P) Ltd, New Delhi, 2019; 99.
3. Susruta.SutraSthan. Shalyapanayaniya. In Shastri, K.A (Ed), Susrutasamhita, 2017; 143). Varanasi: Chaukhambha Sanskrit Sansthan.
4. Sharma S. AshtangaSangraha of Acharya Vagbhata. Varanasi: Chaukhambha Sanskrit Series Office, 2012: 243.
5. Das, S.G. Netrarogachikitsaprokaranam. In Shastri, S.R (Ed), Bhaisajyaratnavali, 2018; 995. Varanasi: ChaukhambaPrakashan.
6. Tripathi I, Tripathi DS. Yogaratnakara. Reprint. Varanasi: Chaukhambhakrishnadas academy, 2010: 792.
7. Tripathi I, Tripathi DS. Yogaratnakara. Reprint. Varanasi: Chaukhambhakrishnadas academy; 2010: 79.
8. Susruta. SutraSthan (2017). Shalyapanayaniya. In Shastri, K.A (Ed), Susrutasamhita (pp. 143). Varanasi: Chaukhambha Sanskrit Sansthan;
9. AshtangaSangraha of Acharya vagbhata Varanasi chaukhambha Sanskrit series-2012, shloka-3, page-226 chap-32.
10. Agnivesa. Snehadhyay. In Tripathi, B (Ed), CharakSamhita, 2009; I: 264. Varanasi: ChaukhambaSurbharatiPrakashan.
11. Sharangadhara Samhita. Shri RadhakrishnaParashar, 3rd Baidyanath Prakashan, 1999; 331.
12. Ehrhardt, Kwang-Jin Kim, Drug Absorption Studies: In Situ, In Vitro and In Silico Models, Springer publication, 2008; 289.
13. Tripathi I, Tripathi DS. Yogaratnakara. Reprint. Varanasi: Chaukhambhakrishnadas academy, 2010; 801.
14. Sastry, J.L.N. DravyagunaVijnana, 2005; II: 321-324. Varanasi: ChaukhambhaOrientalia.

15. Prajapati, S., & Patel, B. R. Phyto Pharmacological Perspective of Yashtimadhu Glycyrrhiza Glabra LINN A Review. *Int J Pharm Biol Arch*, 2013; 4(5): 833-41.
16. Bhavmishra. Dugdhavarga. In Pandey, G.S (Ed), BhavprakashNighantu, 2018; 743. Varanasi: ChaukhambaBharati Academy.
17. Newmark, L.M. (2017). International Milk Genomics Consortium. Retrieved 11 March, 2021, from <https://milkgenomics.org/article/milks-bioactive-ingredients-help-wounds-heal-faster>