

**A SINGLE CASE STUDY: AN AYURVEDIC SURGICAL  
MANAGEMENT OF VARTMASHARKARA W.S.R. TO CONJUNCTIVAL  
CONCRETION BY CHEDAN PASHCHYAT LEKHANA KARMA**

**\*Dr. Archit G. Adhvaryu, \*\*Prof. Vd. Hemangi B. Shukla**

\*3<sup>rd</sup> Year P.G Scholar, Department of Shalakyatantra, GAAC Ahmedabad.

\*\*Professor and HOD Department of Shalakyatantra, GAAC Ahmedabad.

Article Received on 22 Oct. 2025,  
Article Revised on 12 Nov. 2025,  
Article Published on 16 Nov. 2025,

<https://doi.org/10.5281/zenodo.17616812>

**\*Corresponding Author**

**Dr. Archit G. Adhvaryu**

3<sup>rd</sup> Year P.G Scholar, Department  
of Shalakyatantra, GAAC  
Ahmedabad.



**How to cite this Article:** \*Dr. Archit G. Adhvaryu, Prof. Vd. Hemangi B. Shukla. (2025). A Single Case Study: An Ayurvedic Surgical Management of Vartmasharkara W.S.R. To Conjunctival Concretion by Chedan Pashchyat Lekhana Karma. World Journal of Pharmaceutical Research, 14(22), 1147-1153.

This work is licensed under Creative Commons Attribution 4.0 International license.

**ABSTRACT**

As per Ayurveda 'Vartma' refers to the eyelid, which serves as the site for the manifestation of *Vartmagata roga*. *Vartma Sharkara* is one among the 21 types of *Vartmagataroga* described by *Acharya Sushruta*, primarily characterized by *Khara & Sthula pidika* surrounded by *Ghana & Sukshma pidika*. It can be correlated with "conjunctival concretion", A benign entity characterized by single or multiple discrete yellowish-white deposits of varying size. A 35-years-old female patient reported to the *Shalakya Tantra* OPD of GAAC & Hospital Ahmedabad with the complaints of foreign body sensation, itching, and watering from the left eye for the past 10 days, accompanied by photophobia and redness for the past 4-5 days. As per *Acharya Sushruta* treatment of *Vartmasharkara* include *Chedana paschyat Lekhana karma* was administered. After 5 days of treatment, the patient showed complete relief from all the symptoms.

**KEYWORDS:** *Vartmasharkara, Chedana Karma, Lekhana Karma, Khara & Sthula pidika, Ghana & sukshma pidika.*

**INTRODUCTION**

*Vartmasharkara* is one among the 21 types of *Vartmagataroga* described by *Acharya Sushruta*. As per *Acharya Dalhana* in his commentary, *Vartmasharkara* is *Tridosaja*. *Dhatus* which are involved in *Vartmasharkara* are *Rasa, Rakta, Mamsa*.

पिडकाभिः सुसूक्ष्माभिर्धनाभिरभिसंवृता ॥

पिडका या खरा स्थूला सा ज्ञेया वर्त्मशर्करा॥ (Su.Uttar.3/12)

As per Acharya Sushruta, Khara & Sthula pidika surrounded by Sukshma and Ghana pidikas. It can be correlated with conjunctival concretion, a benign entity characterized by single or multiple discrete yellowish-white deposits of varying size. They may be idiopathic and are generally noted in elderly individuals or secondary to chronic conjunctival inflammation and symptoms are Redness, Foreign body sensation of eye, Lacrimation. In allopathic science choice of treatment in symptomatic conjunctival concretion is removal of concretions by 26G or 30G needle under proper hygiene condition. In Ayurveda Acharya Sushruta has mentioned *Chedana karma paschyat Lekhana Karma* for *Vartma Sharkara* so it was selected for the treatment.

## MATERIALS AND METHODS

### CASE REPORT

A 35 year old female patient, reported sudden onset of foreign body sensation and slight itching into left eye. Gradually symptoms increased, due to more itching patient rub the eye so she felt watering from left eye and mild redness was also appeared from left eye. These all complaints were present since 10 days. As associated complaints, she presents with photophobia since 4-5 days. She experienced a gradual increase in foreign body sensation and itching with redness from the left eye, for which she consulted to the *Shalakyatantra* OPD in GAAC & hospital Ahmedabad for Ayurvedic treatment on 25/07/2024.

There was no history of similar complaints among family members. She was following a vegetarian diet. She was working as a sweeper for past 6 years that's why she regularly came into the contact of dust and other etiological factors of Conjunctival concretions. She had no any other complaints. All other general examinations were found to be normal.

### Vitals

1. Pulse: 84/min
2. Temperature: 99° F
3. Respiratory rate: 18/min
4. Blood pressure 126/84 mmHg

**LABORATORY INVESTIGATION****Blood Investigation**

Hb – 11.9gm%, RBC – 3,60,000 /cmm., WBC – 6,900/cmm.

DLC – N (62%), L (34%), E (03%), M (01%)

BT - 1 min 05 sec

CT - 4 min 35 sec

ESR - 21 mm/hour

HIV - -ve

HbsAG - -ve

RBS – 116 mg/dl

**Urine examination**

Physical – normal

Chemical – Normal

Microscopy – P.C. 01 /hpf,

E.C. 00/hpf

**SPECIFIC EXAMINATION****TORCH LIGHT EXAMINATION**

Right eye		Left Eye
Normal	<b>Lashes</b>	Normal
Normal	<b>Eyelid</b>	Concretions(upper lid) 3 in no. <i>Sthula &amp; khara Pidika</i>
Normal	<b>Bulbar Conjunctiva</b>	Mild Congestion
Normal	<b>Palpebral Conjunctiva</b>	Congestion
Normal	<b>Cornea</b>	Normal
Normal	<b>Pupil</b>	Normal
Greyish White	<b>Pupillary glow</b>	Greyish White
Normal	<b>Pupillary reaction</b>	Normal

**VISUALACUTY TEST**

		RT EYE	LT EYE
Distance	B/C	6/6 (p)	6/6 (p)
	P/H	6/9	6/9
Near	B/C	N/6	N/6

**SLIT LAMPEXAMINATION**

Yellowish white compacted deposits of mucous and degenerated epithelial debris into palpebral conjunctiva.

**THERAPEUTIC INTERVENTION (*CHEDANA KARMA PASCHYAT LEKHANA KARMA*)****PURVA KARMA (PREPARATORY PROCEDURE)**

Informed consent was obtained from the patient prior to the procedure. The procedure was conducted in a OT to maintain proper hygiene. The patient was positioned in the supine

position. The instruments used during the procedure which were previously autoclaved, included a No. 15 surgical blade, a B.P. handle. Additional surgical accessories included a *kupi* (bottle), *Sefalika Patra* (leaf of *Nyctanthes arbor-tristis*) sterile cotton, gauze pieces, surgical gloves, and bandaging materials (if needed). Paracaine eye drops were used as topical anaesthesia, and antibiotic eye drops or ointment was also made available (if required). The medicinal substances used were *Go Ghrta* (cow ghee) and *Pratisarana Dravya*, which consisted of *Sunthi* (dry ginger), *Saindhava* (rock salt), and *Madhu* (honey). All vital signs were within normal limits before the procedure.

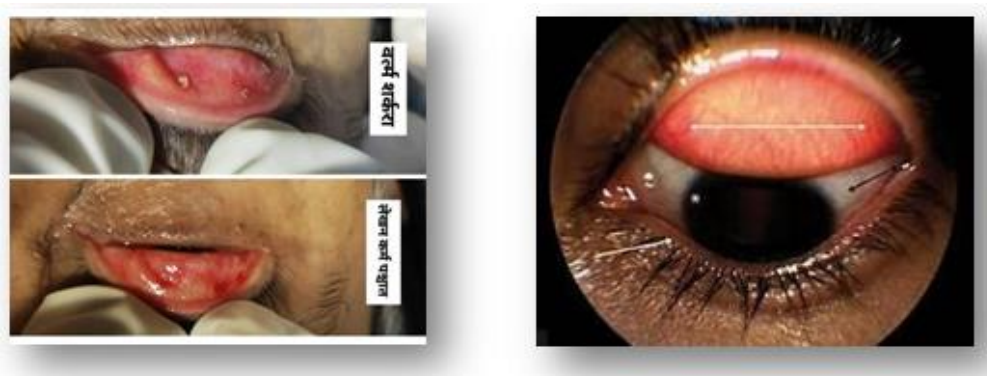
### **PRADHANA KARMA (OPERATIVE PROCEDURE)**

The left upper eyelid was everted with the help of thumb and index finger. The everted eyelid was held straight with thumb and the index finger covered with a piece of linen to prevent against its movement and fell down. The left upper eyelid was wiped with gauze piece. Two drops of the Paracaine eye drops (Topical anaesthesia) was instilled into upper lid. Then as per Acharya *Sushruta* has mentioned in *chikitsa* that to follow *shashtapadankana* karma which is *Chhedana Karma* of *Vartma Sharkara* (Conjunctival Concretion) f/b *lekhana* karma was done with the help of No.15 Surgical Blade (for *Chhedana Karma*) & *Sefalika Patra* (for *lekhana karma*). After that eye lid was wiped with gauze piece. After the subsidence of the bleeding, *Pratisarana* with a medicinal compound consisting of *Sunthi churna*, *Saindhva churna* & *Madhu* was done. Then do *Pariseka* of *Goghrta* was performed.

### **PASHYAT KARMA (POST-OPERATIVE PROCEDURE)**

The patient is advised not to rub or touch the eye following the procedure. The patient was instructed to wear Protective eyewear, particularly in dusty environments. The patient was also instructed to avoid getting water into the eyes while bathing for the next 1 to 2 days. Adequate rest for the eyes was advised, and the patient was concealed to avoid prolonged screen exposure for 24 to 48 hours. The patient was instructed for not to do any Strenuous physical activities, exposure to dusty or smoky surroundings, for at least 3 to 5 days to promote proper healing and prevent complications.

## OBSERVATION AND RESULTS



Following five days of treatment, the patient reported complete resolution of symptoms including foreign body sensation, itching, and watering in the left eye. Additionally, associated complaints such as photophobia and redness had also subsided. The patient was advised to continue adhering to the recommended *Pathya Ahara-Vihara* (wholesome diet and lifestyle) as detailed below. Particular emphasis was given to avoiding exposure to dust and wind, and the use of sunglasses was strongly recommended to help prevent recurrence.

## PATHYA – APATHYA CHART

PATHYA	APATHYA
AHAR	AHAR
<ul style="list-style-type: none"> <li>Old Barley, Wheat, Oats, Rice, Grains, Green Gram, lentil Pulse</li> <li><i>Amalaki</i>, Pomegranate,</li> <li><i>Saindhav</i>, <i>Ghrita</i></li> <li><i>Samshitoshna jala</i></li> </ul>	<ul style="list-style-type: none"> <li>Horse Gram, Black gram, Sprouts</li> <li>Watermelon, Unripe mango, muskmelon. Curd, fish, Mustard oil, spicy food</li> <li><i>Adhyasan</i> (eating soon after a meal before the last meal is digested)</li> <li><i>Amla ahara sevan</i></li> <li>excessive intake of liquid diet and alcoholic beverages</li> </ul>
VIHAR	VIHAR
<ul style="list-style-type: none"> <li><i>Pada prakshalan</i>, <i>padabhyanga</i></li> <li>Maintaining eye and overall Hygiene,</li> </ul>	<ul style="list-style-type: none"> <li><i>Diva Swapna</i> (Day sleeping)</li> <li>Immediate and altered exposure to cold and hot</li> <li>Abnormal sleep habit</li> </ul>
<ul style="list-style-type: none"> <li>Wearing Footwear.</li> <li>Use of sunglasses in excessive sunlight</li> </ul>	<ul style="list-style-type: none"> <li>Viewing very near, very far, shining Fast moving minute objects</li> <li><i>Vega Dharan</i> (suppression of urges)</li> <li><i>Continuous Krodha</i> (anger), <i>Shoka</i> (sorrow), <i>rudan</i> (weeping), <i>kalesh</i> (stress)</li> <li>Fomentation to eye, exposure to smoke, suppression of vomiting</li> </ul>

## DISCUSSION

*Vartmagata roga* as well as Conjunctival ocular diseases have become a special concern for

clinical and basic research. Their impact on quality of life among individuals, annually represent an important issue of investment to find better treatments, particularly to control the effects of chronic diseases which could threat vision and negatively influence day to day activities. In this condition it is important to perform *Chedana* before *Lekhana* as the *Sthula & Khara pidika* will not respond initially to *Lekhana*. *Chedana* will be highly beneficial to remove the concretion of *Vartama Sharkara* and *Lekhana karma* leaves the surface smooth.

## CONCLUSION

In allopathic science choice of treatment is symptomatic for Conjunctival concretion (*VartmaSharakara*), removal of concretions by 26G or 30G needles under proper hygiene condition. As this disease is very much distressing to the patients and could hamper day to day activities as well as recurrence ratio is much higher than others, so for a better alternative is highly promising. By analysing this case, it is proven that *Chedana* followed by *Lekhana* is highly effective to cure the condition. It was noted that after doing this procedure the recurrence ratio of conjunctival concretion is reduced.

## REFERENCES

1. Sushrut Sushrut Samhita commentary by Dalhan Edited by Vd.Yadvji Trikamaji Acharya Surbharti Prakashan, Varanasi.2012. Sutra sthan 1/7.
2. Vagbhatt Astang Hridaya. Commentary by dr. Bhramhanand Tripathi, Chaukhambha Sanskrit pratishthan Delhi, edited with Nirmala Hindi commentary along with special deliberation. Uttar Tantra 16/61.
3. Sushruta Sushruta Samhita commentary by Dalhan Edited by Vd.Yadvji Trikamaji Acharya Surbharti Prakashan, Varanasi.2012. Uttar tantra 3/12.
4. Shushruta Shushruta Samhita commentary by Dalhan Edited by Vd.Yadvji Trikamaji Acharya Surbharti Prakashan, Varanasi.2012. Uttar tantra3/12.
5. Sushruta Sushruta Samhita commentary by Dalhan Edited by Vd.Yadvji Trikamaji Acharya Surbharti Prakashan, Varanasi.2012. Uttar tantra 13/14.
6. Sushruta Sushruta Samhita commentary by Dalhan Edited by Vd.Yadvji Trikamaji Acharya Surbharti Prakashan, Varanasi.2012. Uttar tantra 13/3-7.
7. Sushruta Samhita commentary by Dalhan Edited by Vd.Yadvji Trikamaji Acharya Surbharti Prakashan, Varanasi.2012. Uttar tantra 18/59.
8. Sushruta Samhita commentary by Dalhan Edited by Vd.Yadvji Trikamaji Acharya Surbharti Prakashan, Varanasi.2012. Uttar tantra 18/64-65.

9. Vagbhatt Ashtang Hridaya Commentary by dr. Bhramhanand Tripathi, Chaukhambha Sanskrit pratishthan Delhi, edited with Nirmala Hindi commentary along with special deliberation. Uttar tantra 9/21.
10. Shastrakarma of Shakakyatantra, written by Vd. Hemangi B. Shukla, Published by YUTI Publication, Ahmedabad, 1st edition <https://www.ncbi.nlm.nih.gov/books/NBK560771/>