

A CASE STUDY ON AYURVEDIC MANAGEMENT OF ASHMARI (RENAL CALCULI)

¹*Dr. Heena Khan, ²Dr. Sachin Koli, ³Dr. Niranjana Saraf, ⁴Dr. Vandana Saraf

¹PG Scholar, ²PG Scholar, ³Associate Professor, ⁴Associate Professor,

^{1,2,4}Department of Kayachikitsa, Govt. Dhanwantari Ayurveda College and Hospital Ujjain

(M.P.)

³Department of Swasthavritta & yoga, Govt. Dhanwantari Ayurveda College and Hospital

Ujjain (M.P.)

Article Received on 05 April 2026,
Article Revised on 25 April 2026,
Article Published on 01 May 2026,

<https://doi.org/10.5281/zenodo.20024243>

*Corresponding Author

Dr. Heena Khan

PG Scholar, Department of
Kayachikitsa, Govt. Dhanwantari
Ayurveda College and Hospital
Ujjain (M.P.)



How to cite this Article: ¹Dr. Heena Khan*,
²Dr. Sachin Koli ³Dr. Niranjana Saraf
⁴Dr. Vandana Saraf. (2026). A Case Study on
Ayurvedic Management of Ashmari (Renal
Calculi). World Journal of Pharmaceutical
Research, 15(9), 1347-1353.

This work is licensed under Creative Commons
Attribution 4.0 International license.

ABSTRACT

Renal calculi represent a common urological disorder with a global prevalence ranging from 10–15% and a recurrence rate of nearly 50% within 5 years. In Ayurveda, this condition is described as *Mutrashmari*, one among the *Ashtamahagada*. The present case study describes a 47-year-old male presented with bilateral flank pain, burning micturition, and dysuria. Ultrasonography revealed bilateral renal calculi (right lower pole calyx 4.2 mm; left upper 5.1 mm and lower pole calyx 6.2 mm). The patient was managed with Ayurvedic *Shamana Chikitsa* comprising Chandraprabha Vati, Gokshuradi Guggulu, and Varunadi Kwath for a duration of 60 days. Post-treatment ultrasonography demonstrated complete resolution of calculi along with significant symptomatic relief. The findings suggest that Ayurvedic interventions can effectively manage renal calculi and reduce recurrence.

KEYWORDS: Mutrashmari, Renal calculi, Calyceal stone, Ayurveda, Ashmari.

INTRODUCTION

Renal calculi (urolithiasis) is a common and recurrent urological disorder, increasingly prevalent due to changing lifestyle patterns. It is most frequently observed in individuals

between 20–40 years of age and is influenced by multiple factors such as genetic predisposition, metabolic abnormalities, dehydration, dietary habits, sedentary lifestyle, and mineral content of water. Clinically, it presents with symptoms like flank pain, burning micturition, and dysuria, and may lead to complications such as recurrent hospitalization and, in severe cases, renal failure. Modern management includes pharmacological therapy, diuretics, and surgical interventions such as percutaneous nephrolithotomy and other minimally invasive procedures. Among different types, calcium oxalate stones account for approximately 80% of cases. In Ayurveda, renal calculi can be correlated with Ashmari, which is classified under Mutravaha Srotas Vyadhi and considered one of the Ashtamahagada, indicating its difficult management. According to Acharya Sushruta, Ashmari affects the Basti, one of the Trimarma, thereby emphasizing its clinical significance. Both medical and surgical treatments have been described, with greater emphasis on early diagnosis and conservative management to avoid complications. Various Ayurvedic formulations such as Ghrita, Kwatha, Churna, and Kshara are indicated in the management of Ashmari. Among these, Kwatha preparations are particularly effective due to their Mutrala (diuretic) and Bhedana (lithotriptic) properties, which aid in the disintegration and expulsion of stones. Ashmari is classified into Vataj, Pittaj, Kaphaj, and Shukraj types based on Dosha predominance, with Kaphaja predominance playing a major role in its pathogenesis. In the present case, based on clinical features and radiological findings, the condition can be interpreted as Vata-Kaphaja Ashmari, where Kapha initiates crystal formation and Vata facilitates aggregation and localization within the renal calyces.

CASE STUDY

The present case study describes a 47-year-old male patient who presented with complaints of bilateral flank pain, burning micturition (Mutradaha), and dysuria (Mutrakrichra) for the past 3 months. The pain was intermittent in nature, moderate in intensity, and occasionally radiating towards the groin region. The patient also reported associated symptoms such as increased frequency of micturition, discomfort during urination, and a sensation of incomplete voiding.

There was no history of fever, hematuria, or any major systemic illness. The patient had a history suggestive of inadequate water intake and irregular dietary habits, which may have contributed to the condition. Ultrasonography (USG) of the abdomen revealed bilateral renal calculi, with a calculus measuring 4.2 mm in the lower pole calyx of the right kidney, and

two calculi measuring 5.1 mm in the upper pole and 6.2 mm in the lower pole calyx of the left kidney. Based on the clinical features and radiological findings, the condition was diagnosed as renal calculi (urolithiasis), which can be correlated with Ashmari in Ayurveda.

HISTORY

Symptoms persisted for several weeks with gradual worsening.

PERSONAL HISTORY

- Inadequate water intake
- Irregular dietary habits
- Sedentary lifestyle

INVESTIGATIONS

Before Treatment (USG)

- Right kidney: 4.2 mm calculus (lower calyx)
- Left kidney: 5.1 mm (upper calyx), 6.2 mm (lower calyx)
- No hydronephrosis

ASHTAVIDHA PARIKSHA

On examination through Ashtavidha Pariksha, the patient presented with the following findings

- **Nadi (Pulse):** Vata-Pittaja type
- **Mala (Stool):** Samyak (normal)
- **Mutra (Urine):** Presence of *daha* (burning micturition)
- **Jihva (Tongue):** Sama (coated)
- **Shabda (Speech):** Prakrita (normal)
- **Sparsha (Skin temperature):** Ushna (warm to touch)
- **Druka (Eyes):** Prakrita (normal)
- **Akruti (Body build):** Madhyama (moderate physique).

GENERAL PHYSICAL EXAMINATION

On general physical examination, all parameters of the patient were found to be within normal limits. The patient was conscious, well-oriented, and afebrile, with stable vital signs. No pallor, icterus, cyanosis, clubbing, lymphadenopathy, or edema was observed.

THERAPEUTIC INTERVENTION

The patient was managed with *Shamana Chikitsa* for a duration of **60 days** using the following medications.

S. No.	Drug Name	Dose	Anupana	Duration	Therapeutic Action
1	Chandraprabha Vati	2 tablets twice daily	Lukewarm water	60 days	Mutrala, Deepana, Shothahara, Vata-Kapha Shamana
2	Gokshuradi Guggulu	2 tablets twice daily	Lukewarm water	60 days	Mutrala, Ashmarighna, Srotoshodhana
3	Varunadi Kwath	40 ml twice daily	Empty stomach (preferably)	60 days	Ashmarighna, Mutrala, Lekhana

TREATMENT APPROACH

- **Type of Chikitsa:** Shamana Chikitsa
- **Line of Management**
- Ashmari Bhedana (stone disintegration)
- Mutrala (diuresis)
- Srotoshodhana (channel purification)
- Vata-Kapha Shamana

PATHYA – APATHYA

Pathya

- Increased fluid intake
- Coconut water, barley water
- Light diet

Apathya

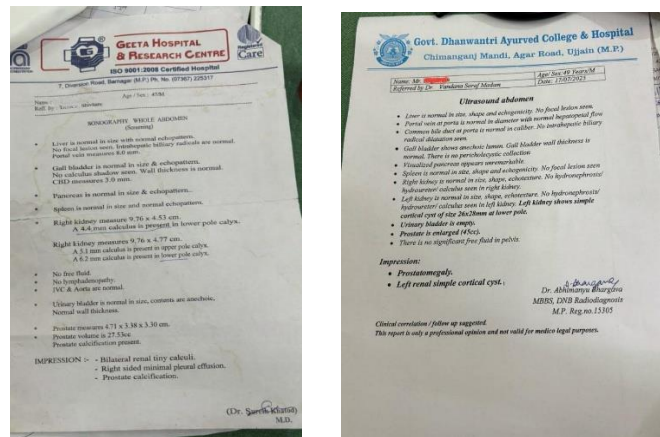
- Spicy, oily food
- Low water intake
- Sedentary habits

RESULT

Parameter	Before Treatment	After Treatment
Pain	Present	Absent
Burning micturition	Present	Absent
Dysuria	Present	Absent
USG findings	Multiple calculi	No calculi

Follow-up USG confirmed **complete resolution of calyceal stones**.

REPORT



DISCUSSION

Renal calculi, particularly those located in the calyceal system, represent an early stage of stone formation where conservative management can be highly effective. In the present case, the calculi were small in size (4–6 mm), favoring spontaneous expulsion with appropriate therapy. From an Ayurvedic perspective, Mutrashmari involves predominance of Kapha Dosha, which initiates crystal formation due to its *Snigdha* and *Guru* properties, along with Vata Dosha, which facilitates drying, aggregation, and localization of crystals. The involvement of Mutravaha Srotas leads to *Srotorodha* and impaired urinary flow. The treatment protocol included Chandraprabha Vati, Gokshuradi Guggulu, and Varunadi Kwath, which act synergistically. Chandraprabha Vati possesses Mutrala, Deepana, and Shothahara properties, helping to increase urine output, reduce inflammation, and prevent infection. Gokshuradi Guggulu exhibits Mutrala and Ashmarighna actions; its key ingredient *Gokshura* has diuretic and antiurolithiatic effects, while *Guggulu* provides anti-inflammatory benefits.

Varunadi Kwath, especially *Varuna* (*Crataeva nurvala*), shows significant lithotriptic, diuretic, and anti-inflammatory properties, aiding in reducing stone size and facilitating expulsion. Together, these formulations help in breaking calculi, relieving symptoms, and preventing recurrence.

The combined pharmacological actions of these formulations include

- **Diuretic effect** – increases urine volume, reducing supersaturation of stone-forming salts
- **Antiurolithiatic activity** – inhibits crystal nucleation, aggregation, and growth
- **Anti-inflammatory effect** – reduces irritation and edema in urinary tract
- **Antioxidant activity** – protects renal epithelium from oxidative damage

- **Antimicrobial action** – prevents infection-related stone formation

CONCLUSION

The present case study highlights the significant role of Ayurvedic management in the treatment of *Mutrashmari* (renal calculi), especially in early-stage calyceal stones. The administration of Chandraprabha Vati, Gokshuradi Guggulu, and Varunadi Kwath for 60 days resulted in complete clearance of calculi along with marked improvement in clinical symptoms. The therapeutic efficacy can be attributed to the synergistic action of *Mutrala*, *Ashmarighna*, and *Srotoshodhana* properties, supported by pharmacological activities such as diuretic, antiurolithiatic, anti-inflammatory, antioxidant, and antimicrobial effects. These interventions not only aid in the disintegration and expulsion of stones but also address the underlying pathogenesis, thereby reducing the chances of recurrence. This case emphasizes that Ayurvedic treatment can serve as a safe, effective, and non-invasive alternative in the management of renal calculi. However, further large-scale clinical studies are necessary to validate these findings and establish standard.

AUTHOR DECLARATION

- Informed consent was obtained from the patient
- No conflict of interest
- No funding received
- Ethical standards maintained.

REFERENCES

1. Sharma RK, Dash B. *Charaka Samhita*. Varanasi: Chowkhamba Sanskrit Series Office, 2014.
2. Shastri AD. *Sushruta Samhita*. Varanasi: Chaukhambha Sanskrit Sansthan, 2012.
3. Murthy KRS. *Ashtanga Hridaya*. Varanasi: Chaukhambha Krishnadas Academy; 2010.
4. Chunekar KC. *Bhavaprakasha Nighantu*. Varanasi: Chaukhambha Bharati Academy, 2013.
5. Tripathi B. *Madhava Nidana*. Varanasi: Chaukhambha Surbharati Prakashan, 2012.
6. Sharma PV. *Dravyaguna Vijnana*. Varanasi: Chaukhambha Bharati Academy, 2005.
7. Walker BR, Colledge NR, Ralston SH, Penman ID. *Davidson's Principles and Practice of Medicine*. 23rd ed. Elsevier, 2018.
8. Jameson JL, Fauci AS, Kasper DL, Hauser SL, Longo DL, Loscalzo J. *Harrison's Principles of Internal Medicine*. 20th ed. McGraw Hill., 2018.

9. Wein AJ, Kavoussi LR, Partin AW, Peters CA. *Campbell-Walsh Urology*. 11th ed. Elsevier, 2016.
10. Pearle MS, Calhoun EA, Curhan GC. Urologic diseases in America project: urolithiasis. *J Urol.*, 2005; 173(3): 848–857.
11. Worcester EM, Coe FL. Clinical practice: calcium kidney stones. *N Engl J Med.*, 2010; 363(10): 954–963.
12. Türk C, Neisius A, Petrik A, et al. EAU guidelines on urolithiasis. *European Association of Urology.*, 2022.
13. Chhatre S, Nesari T, Somani G, Kanchan D, Sathaye S. Phytopharmacological review of *Tribulus terrestris*. *Pharmacogn Rev.*, 2014; 8(15): 45–51.
14. Varalakshmi P, Shamila Y, Latha E. Effect of *Crataeva nurvala* in experimental urolithiasis. *J Ethnopharmacol.*, 1990; 28(3): 313–321.
15. Patel PK, Patel MA, Vyas BA. Antiurolithiatic activity of herbal formulations. *Int J Pharm Sci Rev Res.*, 2012; 12(2): 45–49.
16. Bashir S, Gilani AH. Antiurolithiatic effect of herbal medicines. *Urol Res.*, 2009; 37(5): 285–292.
17. *Galore International Journal of Applied Sciences and Humanities*, Volume 10, Issue 1: January–March 2026; Available from: www.gijas.com.
18. *European Journal of Pharmaceutical and Medical Research (EJPMR).*, Volume 7, Issue 11: 2020; Available from: www.ejpmr.com.