

## AYURVEDIC MANAGEMENT OF ACUTE FISSURE-IN-ANO (PARIKARTIKA) WITH TRIVRUT TRIPHALA YOG (ORAL ADMINISTRATION) AND YASHTIMADHU GHRITA (LOCAL APPLICATION): A CLINICAL SINGLE CASE STUDY

Dr. Shital Ajit Lanke<sup>1\*</sup>, Dr. Ramesh Baliram Jadhav<sup>2</sup>

<sup>1</sup>Final Year Post Graduate Scholar, Department of Shalyatantra, R.A. Podar Ayurvedic College, Worli, Mumbai, Maharashtra, India.

<sup>2</sup>Associate Professor, Department of Shalyatantra, R.A. Podar Ayurvedic College, Worli, Mumbai, Maharashtra, India.

Article Received on 15 May 2026,  
Article Revised on 05 June 2026,  
Article Published on 16 June 2026,  
<https://doi.org/10.5281/zenodo.20729368>

### \*Corresponding Author

Dr. Shital Ajit Lanke

Final Year Post Graduate Scholar,  
Department of Shalyatantra, R.A.  
Podar Ayurvedic College, Worli,  
Mumbai, Maharashtra, India.



**How to cite this Article:** Dr. Shital Ajit Lanke<sup>1\*</sup>, Dr. Ramesh Baliram Jadhav<sup>2</sup>. (2026). Ayurvedic Management Of Acute Fissure-In-Ano (Parikartika) With Trivrut Triphala Yog (Oral Administration) And Yashtimadhu Ghrita (Local Application): A Clinical Single Case Study. World Journal of Pharmaceutical Research, 15(12), 1937-1942.

This work is licensed under Creative Commons Attribution 4.0 International license.

### ABSTRACT

*Parikartika*, commonly known as fissure-in-ano, ranks among the prevalent anorectal disorders. Changing lifestyle, increased stress, and disturbed sleep habits contribute to *Agnimandya*, which is considered the root cause of *Parikartika*. Acharya Charaka has described Trivrut Triphala Yog for anorectal disorders in *Charaka Chikitsasthana* 14/66. Trivrut is also described as a *Sukhavirechaka Dravya* in Ayurvedic literature. A 34-year-old male patient presented with a longitudinal ulcer at the 6 o'clock position of the anal verge associated with sharp cutting pain, per rectal bleeding, and severe sphincter spasm. The patient was treated with Trivrut Triphala Yog administered orally along with local application of Yashtimadhu Ghrita. The patient was advised dietary modifications, sitz bath, and lifestyle correction. Significant improvement was observed within 10 days of treatment. Follow-up after two months revealed no recurrence. The present case study demonstrates the efficacy of

Trivrut Triphala Yog and Yashtimadhu Ghrita in acute fissure-in-ano (*Parikartika*).

**KEYWORDS:** Parikartika, Fissure-in-Ano, Trivrut Triphala Yog, Yashtimadhu Ghrita, Sukhavirechana, Anulomana.

## 1. INTRODUCTION

In Ayurvedic *Samhitas*, *Parikartika* has been described in different contexts. In *Charaka Samhita* it is described as a complication of *Virechana Vyapad*. In *Sushruta Samhita* it is described under *Basti Vyapad* and in *Kashyapa Samhita* under *Garbhini Vyapad*. Fissure-in-ano is one of the most common and painful anorectal disorders. It is frequently observed in young adults and pregnant women. Severe pain occurs because of injury to the somatic nerve supply of the anal region.

Modern management includes analgesics, antibiotics, laxatives, and ointments as conservative treatment. Surgical interventions such as anal dilatation, sphincterotomy, and fissurectomy are also employed, although they may be associated with complications.

In Ayurveda, Acharya Sushruta described Trivrut Triphala Yog for anorectal disorders and Trivrut as a *Sukhavirechaka Dravya*.

The *Vatashamaka* action of Yashtimadhu Ghrita provides smooth muscle relaxation, thereby reducing pain during defecation. Its *Pittashamaka* and *Vranaropaka* properties help reduce burning sensation and promote healing.

Considering these properties, the present case study was undertaken.

## 2. CASE REPORT

A 34-year-old male patient presented with:

- Sharp cutting pain before and after defecation for 20 days.
- Per rectal bleeding appearing as streaks on toilet paper and occasionally as drops.
- Hard stool associated with severe pain.
- Pain lasting approximately 3–4 hours after defecation.
- Frequent episodes of bleeding affecting quality of life.
- Longitudinal ulcer measuring 12 mm at the 6 o'clock position.
- Severe sphincter spasm.

## 3. MATERIALS AND METHODS

### Study Centre

R.A. Podar Ayurved Hospital, Mumbai.

## Study Design

Clinical Single Case Study.

## Treatment Protocol

1. Trivrut Churna 1 g BID for 15 days with *Koshnajala*.
2. Triphala Churna 3 g BID for 15 days with *Koshnajala*.
3. Yashtimadhu Ghrita 2 ml BID for 15 days for local application in the anal region.

## Mode of Action of Drugs

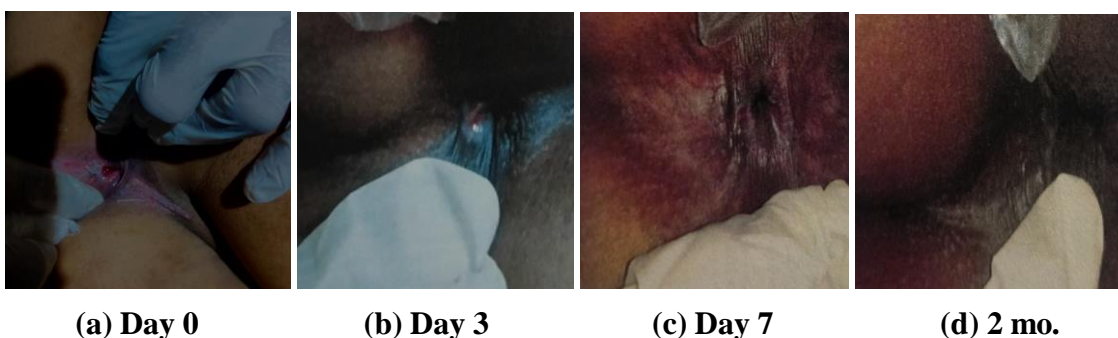
**Table 1: Probable Mode of Action of Drugs.**

Drug	
Trivrut Churna	<i>Sukhavirechaka, Vatanulomana, Kapha-Pittashamaka</i> , useful in anorectal disorders.
Triphala Churna	Deepana, Pachana, Anulomana, Tridoshashamaka, Vranaropaka. Yashtimadhu Ghrita Vatashamaka, Pittashamaka, Dahashamaka, Vedanasthapana, Shothahara, Vranaropaka.

## 4. RESULTS

**Table 2: Regression of Symptoms During Treatment.**

Symptoms	Day 0	Day 3	Day 7	Day 10	2 Months
Sharp Cutting Pain	+++	+	0	0	0
Severity of Pain	+++	+	0	0	0
Pain Duration	2–3 hrs	<1 hr	No Pain	No Pain	No Pain
P/R Bleeding	+++	+	0	0	0
Size of Ulcer	12 mm	7 mm	3 mm	0	0
Sphincter Spasm	+++	+	0	0	0



**Figure 1: Clinical progression and healing during treatment and follow-up.**

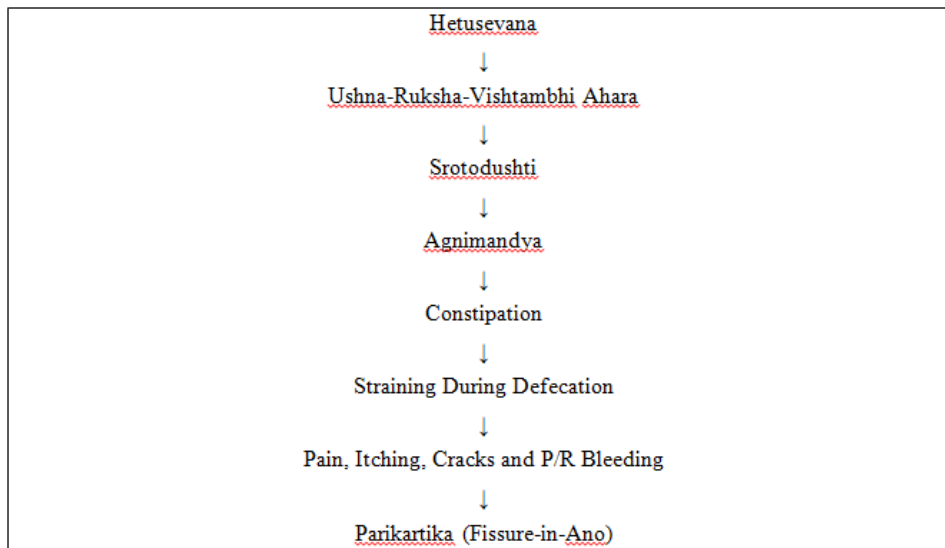
## 5. DISCUSSION

### Hetu

**Table 3: Identified Hetu in the Present Case.**

<p>Aharaja Hetu Viharaja Hetu Manasika Hetu          Bakery products; <i>Ruksha Ahara</i>; <i>Amla-Lavana Ahara</i>; alcohol consumption; low fibre intake; low water intake.  <i>Jagarana</i> (late-night sleeping). <i>Chinta</i>; <i>Krodha</i>.</p>
---

### Samprapti



**Figure 2: Samprapti of Parikartika.**

### Pathya

- Fibre-rich diet
- Increased fluid intake
- Buttermilk
- One teaspoon cow ghee before meals
- Avoid late-night sleeping
- Sitz bath twice daily

## 6. CONCLUSION

Fissure-in-ano requires prolonged healing because constipation and *Agnimandya* repeatedly traumatize the fissure during defecation.

Trivrut Triphala Yog corrects constipation and *Agnimandya*, thereby addressing the root cause of disease. The formulation improves digestion and promotes healing.

Local application of Yashtimadhu Ghrita relaxes the sphincter through its *Vatashamaka* action and accelerates wound healing because of its *Vranaropaka* property.

## REFERENCES

1. Akkapulu N, Dere O, Zaim G, Soy HE, Ozmen T, Dogrul AB. A retrospective analysis of 93 cases with anorectal abscess in a rural state hospital. *Ulus Cerrahi Derg*, 2015; 31: 5–8. doi: 10.5152/UCD.2014.2453.
2. Prasad ML, Read DR, Abcarian H. Supralelevator abscess: diagnosis and treatment. *Dis Colon Rectum*, 1981; 24: 456–461. doi: 10.1007/BF02626783.
3. Read DR, Abcarian H. A prospective survey of 474 patients with anorectal abscess. *Dis Colon Rectum*, 1979; 22: 566–568. doi: 10.1007/BF02587008.
4. Van Onkelen RS, Gosselink MP, Schouten WR. Treatment of anal fistulas with high intersphincteric extension. *Dis Colon Rectum*, 2013; 56: 987–991. doi: 10.1097/DCR.0b013e3182908eb6.
5. Gordon PH. Anorectal abscesses and fistula-in-ano. In: Gordon PH, Nivatvongs S, editors. *Principles and Practice of Surgery for the Colon, Rectum, and Anus*. 3rd ed. New York: Informa Healthcare; 2007; 191–233.
6. Garcia-Granero A, Granero-Castro P, Frasson M, et al. Management of cryptoglandular supralelevator abscesses in the magnetic resonance imaging era: case series. *Int J Colorectal Dis.*, 2014; 29: 1557–1564. doi: 10.1007/s00384-014-2028-2.
7. Beets-Tan RG, Beets GL, van der Hoop AG, et al. Preoperative MR imaging of anal fistulas: does it really help the surgeon? *Radiology*, 2001; 218: 75–84. doi: 10.1148/radiology.218.1.r01ja0575.
8. Morris J, Spencer JA, Ambrose NS. MR imaging classification of perianal fistulas and its implications for patient management. *Radiographics*, 2000; 20: 623–635. doi: 10.1148/radiographics.20.3.g00ma13623.
9. Ommer A, Herold A, Berg E, et al. German S3 guideline: anal abscess. *Int J Colorectal Dis.*, 2012; 27: 831–837. doi: 10.1007/s00384-012-1430-x.
10. Garcia-Granero E, Granero-Castro P, Frasson M, et al. The use of an endostapler in the treatment of supralelevator abscess of intersphincteric origin. *Colorectal Dis.*, 2014; 16: O335–O338. doi: 10.1111/codi.12670.
11. Agha RA, Borrelli MR, Farwana R, et al. The SCARE 2018 statement: updating consensus surgical CAse REport (SCARE) guidelines. *Int J Surg*, 2018; 60: 132–136. doi: 10.1016/j.ijsu.2018.10.028.

12. Khanna V, Raina A, Sharma A, Pargotra PP. Critical analysis of Kasisadi Ghrita in Parikartika (fissure-in-ano). *AYUSHDHARA – An International Journal of Research in AYUSH and Allied Systems*, 2016; 3(3): 725–727.
13. Shekokar AV, Borkar KM, Patil MA, Jagtap V. A comparative study of Yashtimadhukadi Varti and diclofenac sodium suppositories in the management of Parikartika with special reference to fissure-in-ano. *International Journal of Ayurveda*. 2012.
14. Patil PP. Effect of Vedanantaka Malahara and Jatyadi Ghrita in the management of Parikartika (fissure-in-ano). *International Journal of Ayurveda*, 2010.
15. Shivakumara B, Shridhara Rao SM. Management of Parikartika (acute fissure in ano) with Patoladi Taila Matra Basti: a case study. *Journal of Ayurveda and Integrated Medical Science*, 2020.
16. Yeli P, Musalekar S. Management of Parikartika with Karpoora Ghrita: a case study. *Journal of Ayurveda and Integrated Medical Science*, 2019.
17. Patel JR, Dudhamal TS. A comparative clinical study of Yashtimadhu Ghrita and lignocaine-nifedipine ointment in the management of Parikartika (acute fissure-in-ano). *AYU: An International Quarterly Journal of Research in Ayurveda*, 2017; 38(1–2): 46–51.
18. Jagdhane CD. Evaluation of Yashtimadhu Tail Matrabasti efficacy in the treatment of acute fissure in ano. *World Journal of Pharmaceutical Research*, 2017; 6(5): 992–996.
19. Sattigeri V. A clinical study of Yashtimadhu Ghritha Pichu in the management of Parikartika with special reference to fissure-in-ano. *International Ayurvedic Journal.*, 2019; 7(7). Ayurved Mahavidyalaya Hubli, Karnataka.