

## SHALYAJ NAADIVRANA – A CASE REPORT

Sanchita Rani<sup>1\*</sup>, Dr. Ramesh Kaundal<sup>2</sup> and Dr. Rohit Parmar<sup>3</sup><sup>1</sup>PG Scholar, Department of Dravyaguna, Government Ayurvedic College Patiala, Punjab.<sup>2</sup>Lecturer, Department of Shalya Tantra, Government Ayurvedic College Patiala, Punjab.<sup>3</sup>PG Scholar, Department of RSBK, Government Ayurvedic College Patiala, Punjab.Article Received on  
20 February 2024,Revised on 11 March 2024,  
Accepted on 31 March 2024

DOI: 10.20959/wjpr20247-31907



\*Corresponding Author

Dr. Sanchita Rani

PG Scholar, Department of  
Dravyaguna, Government  
Ayurvedic College Patiala,  
Punjab.

## ABSTRACT

Pilonidal sinus is an acquired condition affecting the sacrococcygeal region, characterized by the formation of sinus tracts and recurrent abscesses. Traditional treatment modalities often exhibit limitation in terms of recurrence rates, prolonged healing times and post operative complications. *Kshara Sutra*, a unique *Ayurvedic* therapy involving medicated alkaline thread. In the present Era the cases of Pilonidal sinus are collected to be 26 per 1,00,000 people.<sup>[1]</sup> It occurs 2.2 times more often in men then in women. *Acharya Sushruta Shalyaj Naadivrana* compared with pilonidal sinus. The role of *Kshara Sutra* in pilonidal sinus is very effective. The chances of reoccurrence are very less. *Acharya Sushruta* explained the description on *Shalyaj Nadi Vrana* which is mentioned in *Nidaan Sthana* 10<sup>th</sup> *Visarpanaadistana Roga Nidaan* and its *Chikitsa* in 17<sup>th</sup> chapter.

**KEYWORDS:** *Shalyaj Naadivrana*, PNS (Pilonidal sinus), *Ksharasutra*.

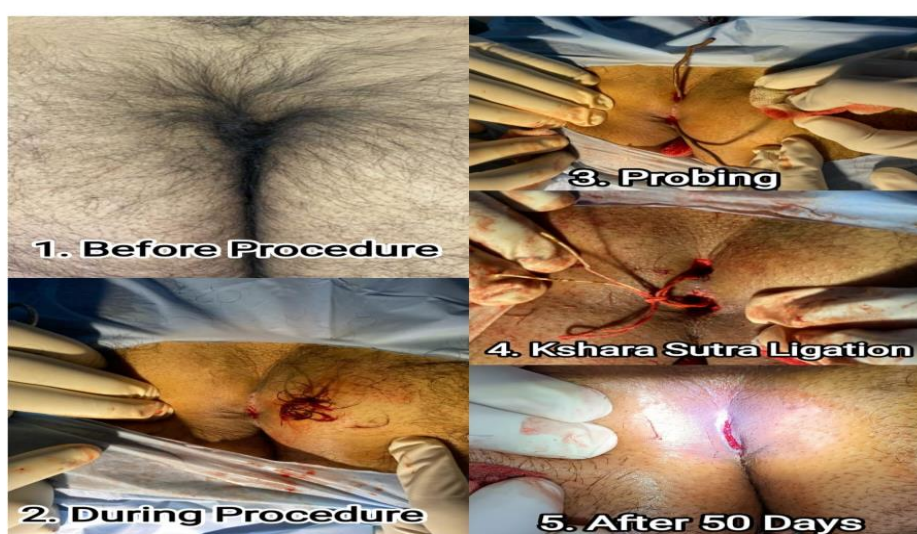
## INTRODUCTION

Pilonidal sinus means nest of hairs in Greek. It is also called Jeep-bottom because it is very common in jeep drivers. It is more common in dark people than fair people.<sup>[2]</sup> The age incidence of the appearance of pilonidal sinus (82% occur between the ages of 20 and 29 years).<sup>[3]</sup> It is commonly seen in adult males and hardly in females. While sitting the buttocks move and hair is broken off by friction and collect in the cleft. When the toilet paper is used hair entangled in fecal matter will also be swept into the cleft. Such loose hair travel down the intergluteal furrow to penetrate the soft and moistened skin at that region or enter the open mouth of sudoriferous gland. After the initial entry, dermatitis and inflammation start around

the loose hair and once the sinus is formed, intermittent negative pressure of the area may suck other loose hair into the pit. This type of sinus is lined by stratified squamous epithelium. The sinus extends into the subcutaneous tissue. Tuft of hair is always seen within such sinus embedded in granulation tissue.<sup>[4]</sup>

## CASE REPORT

A 21 years old male came at Government Ayurvedic Hospital, Patiala in *Shalya Tantra* O.P.D with the complaints of pus discharge from the external opening in the natal cleft, pain at sacrococcygeal region for 8 months. He was taking allopathy medicine for PNS but got no relief. After local examination and relevant investigations, it was diagnosed as the case of Pilonidal Sinus. Before procedure CBC, ESR, LFT, RFT, HIV, HCV, VDRL, HB<sub>s</sub>Ag, BT, CT, FBS, Prothrombin tests were performed. All investigations were within normal limits. Next day patient came for *Kshara Sutra Karma*. The patient was placed on the operating table in the prone position. Proper painting and draping done. After embedded hair follicles were removed out. The probe was inserted into the tract and ligatation of the *Kshara Sutra* was done. Under aseptic conditions dressing given with sterile gauze pad. After checked vitals and urine output, patient was discharged with 6 hours of stay. *Gandhak Rasayan* 2 BD after meal, *Triphala Guggulu* 2 BD after meal orally and *Jatyadi Taila* for local application was given. Patient came for dressing on next day. Patient was advised to maintain local hygiene, keep the area hair free, healthy diet and lifestyle and to avoid sitting for long time and on hard surface. The *Kshara Sutra* was changed weekly for 6 sittings.



## DISCUSSION AND CONCLUSION

*Kshara Sutra* therapy has emerged as a promising in the management of pilonidal sinus due to its unique mechanism of action and favorable clinical outcomes. *Kshara* have *Chhedana*, *Lekhana*, *Ropana*, *Shodhana*, *Tridoshahara* and alkaline properties, and the medicated thread used in *Kshara Sutra* therapy contribute to its efficacy in promoting wound healing, reducing inflammation, and destroying unhealthy tissues. One of the key advantages of *Kshara Sutra* therapy is its ability to target the sinus tracts and diseased tissues while sparing the healthy surrounding tissues. This targeted approach minimizes tissue damage, reduces the risk of recurrence, and promotes faster healing compared to conventional surgical techniques such as excision and primary closure or open wound healing.

## REFERENCES

1. <https://www.ncbi.nlm.nih.gov/pmc/articles/PMC2996578/>
2. K Rajgopal Shenoy, Manipal manual of surgery, Cbs publishers & distributors pvt.ltd, fourth edition, 804.
3. NORMAN S. WILLIAMS, Bailey and love's short practice of surgery, publisher CRC Press taylor & francis group, 2018; 27: 1347.
4. Dr. Praveen kumar, diagnosis and management of anorectal diseases, choukhamba sanskrita pratishthan new delhi, 2020; 281.