

IMPACT OF BASTI THERAPY ON MATERNAL WEIGHT GAIN AND FETAL OUTCOME IN AN UNDERWEIGHT PRIMIGRAVIDA: AN AYURVEDIC CASE REPORT

*¹Dr. Aishwarya Sajjan, ²Dr. Anupama V.

¹Final Year Post Graduate Scholar, Dept. of Prasuti Tantra evam Stri Roga, Sri.

Kalabhyraveswara Swamy Ayurvedic Medical College, Hospital and Research Center,
Bangalore, Karnataka, India.

²Professor & HOD, Dept. of Prasuti Tantra evam Stri Roga, Sri. Kalabhyraveswara Swamy
Ayurvedic Medical College, Hospital and Research Center, Bangalore, Karnataka, India.

Article Received on 05 Dec. 2025,
Article Revised on 25 Dec. 2025,
Article Published on 01 Jan. 2026,
<https://doi.org/10.5281/zenodo.18152490>

*Corresponding Author

Dr. Aishwarya Sajjan

Final Year Post Graduate Scholar,
Dept. of Prasuti Tantra evam Stri
Roga, Sri. Kalabhyraveswara Swamy
Ayurvedic Medical College, Hospital
and Research Center, Bangalore,
Karnataka, India.
aishwaryasajjan6499@gmail.com,



How to cite this Article: *¹Dr. Aishwarya Sajjan, ²Dr. Anupama V. (2026). Impact Of Basti Therapy On Maternal Weight Gain And Fetal Outcome In An Underweight Primigravida: An Ayurvedic Case Report. World Journal of Pharmaceutical Research, 15(1), 1363–1373.
This work is licensed under Creative Commons Attribution 4.0 International license.

ABSTRACT

Background: Maternal nutrition before and during pregnancy is one of the important determinants of pregnancy outcome. Pre-pregnancy body mass index (BMI), gestational weight gain, and gestational age play a crucial role in determining maternal and fetal health. Underweight pregnant women are at increased risk of intrauterine growth retardation (IUGR) and low birth weight infants, while Ayurveda describes that inadequate *Ahāra* leads to *Vāta* aggravation, poor formation of *Rasa Dhātu*, and insufficient nourishment of the fetus. Thus, both systems clearly highlight that maternal undernutrition directly affects fetal growth and development. **Objective:** To evaluate the role of Basti therapies in improving maternal weight gain and fetal outcome in an underweight primigravida. **Materials and Methods:** A 20-year-old primigravida with a body weight of 34 kg was managed with *Kṣīrāṇḍa Basti* and *Anuvāsana Basti* with *Kṣīrabala Taila* during the 5th and 7th months of pregnancy. *Mātrā Basti* with *Sukha Prasava Ghrta*

and *Yoni Pichu* with *Kṣīrabala Taila* were administered after 37 weeks. **Results:** Maternal weight increased from 34 kg in the first trimester to 46 kg by the third trimester. The patient delivered a healthy full-term neonate weighing 2.5 kg through normal vaginal delivery

without maternal or neonatal complications. **Conclusion:** Appropriately selected Basti therapies during pregnancy can be beneficial in improving maternal nutrition, regulating *Vāta*, and supporting normal fetal growth.

KEYWORDS: Kshiranda basti, kheerabala taila, IUGR, Garbhini karshya, Malnutrition.

INTRODUCTION

Pregnancy is a crucial phase in a woman's life, associated with significant physiological and metabolic changes, during which nutritional requirements increase to support maternal health and optimal fetal growth. The nutritional state of the mother before and during pregnancy, along with factors such as pre-pregnancy body mass index, gestational weight gain, and gestational age, plays an important role in determining pregnancy outcomes.

Underweight women at conception often fail to achieve adequate gestational weight gain, resulting in growth-retarded or small-for-date infants, and are therefore considered an at-risk group, particularly in developing countries where maternal undernutrition is prevalent.

Ayurveda emphasizes *Garbhiṇī Paricharya* for proper nourishment of both mother and fetus and recognizes the pivotal role of *Vāta Doṣa* in *Garbha Dhāraṇa* and *Garbha Poṣaṇa*. Inadequate intake of wholesome *Ahāra* leads to *Vāta* aggravation, improper formation of *Ahāra Rasa*, and impaired circulation through the *Rasavahā Nāḍī*, resulting in *Rasa Dhātu Kṣaya* and defective fetal nourishment. This condition is described in the classics as *Upaviṣṭaka*, *Upaśuṣka*, or *Nāgodara*, which closely resembles the modern concept of fetal growth restriction. *Basti Chikitsā*, particularly *Bṛṃhaṇa* and *Balya* therapies such as *Kṣīrāṇḍa Basti* and *Kṣīrabala Taila Anuvāsana Basti*, along with *Mātrā Basti* and *Yoni Pichu* using *Kṣīrabala Taila* for *Vāta Anulomana*, are advocated to improve maternal nutritional status, support fetal growth, and facilitate normal delivery.

AIM AND OBJECTIVES

Aim

To assess the effect of *Kṣīrāṇḍa Basti* along with *Ksheerabala taila basti* on maternal weight gain and fetal outcome in an underweight primigravida.

Objectives

1. To improve maternal nutritional status
2. To promote adequate gestational weight gain

3. To support normal fetal growth and prevent IUGR

CASE REPORT

A 20-year-old primigravida with amenorrhea of four months attended the OPD of Prasuti Tantra evam Stri Roga, SKAMCH & RC, Bengaluru, on 11-07-2025 for antenatal care. She complained of generalized weakness, reduced appetite, and aversion to food for the past 1–2 months. On examination, the patient was underweight with a body weight of 34 kg.

Past history- Not a K/C/O DM, HTN, Thyroid dysfunction, asthma, epilepsy etc.

Personal History- The patient was on a vegetarian diet with reduced appetite. Bowel habits were constipated for one month. Urinary frequency was 4–5 times per day. Sleep was sound.

Married life-6 months

Menstrual and Obstetric History

- Menstrual cycle: Regular
- Duration of bleeding: 1–2 days
- Amount: Scanty
- Dysmenorrhea: Present
- Obstetric status: G1P0A0L0
- LMP: 20-02-2025
- Period of gestation: 19 weeks 6 days
- EDD: 27-11-2025

GENERAL EXAMINATION

Built: Illbuilt

Nourishment: Malnourished

Pulse: 74/min.

BP: 110/70mmhg

Temperature: 97.2F

Respiratory Rate: 24 Cycles/min

Height: 146cm

Weight: 34kg

BMI: 16 kg/m²

Tongue: Uncoated

Pallor/Icterus/Cyanosis/Clubbing/Edema/Lymphadenopathy: Absent.

ASTHA STHANA PAREEKSHA

1. *Nadi: Pitta Pradhana*
2. *Pulse: 74 bpm*
3. *Mala: Badha*
4. *Mutra: 4-5 times a day*
5. *Jiwaha: Aalipta*
6. *Shabda: Utpatti-+*
7. *Grahana - +*
8. *Sparsha: Anushna Sheeta*
9. *Drik: Prakruta*
10. *Akruti: Avara*

DASHAVIDHA PAREEKSHA

1. *Prakruti: Vata pitta*
2. *Vikruti: Vatapitta, Hetu: Asatyma and Ahittakara Ahara and Dauhruda Avastha*
3. *Sara: AVARA*
4. *Satmya: Mishrarasa Satmya*
5. *Pramana: Bhara: 34 kg*
6. *Darighya: 146cm*
7. *Satva:Avara*
8. *Ahara Sakti: Avara*
9. *VyayamaSakti: Avara*
10. *Vaya: Madhyam*

SYSTEMIC EXAMINATION

1. Central Nervous System

Patient is conscious

Well oriented to time, place and person

2. Cardio Vascular System

Inspection: No distended vessels over neck or chest

Palpation: Apex beat palpable at 5th intercostal space

Percussion: Cardiac dullness present on left side

Auscultation: S1 S2 heard no added sounds

3. Respiratory system

Inspection Shape of chest: Bilaterally Symmetrical

Movement symmetrical RR 18 cycles/min

Palpation: Trachea: Centrally placed.

Percussion: Resonant over the lung field except card

4. GIT- Anoroxia- present

Constipation- present

Epigastric pain -absent

Nausea-absent

Vomiting –absent

ANTENATAL EXAMINATION

Inspection :P/A- Stria gravida present

Palpation:P/A-Uterus palpable

Fetal movements – Appreciable

Auscultation-156-158bpm

Percussion-not done

P/S and P/V -not done

Breast examination-Soft, Nontender

INTERVENTION DETAILS

Table 1: Treatment Schedule.

Date	Gestational period	Therapy	Duration
USG-30 June 2025	A Single Intrauterine Pregnancy corresponding to 18weeks 1 day. No fetal structural anomaly is detected at this stage. EFW- 224gram+-33grams Liquor normal		
11 TH July 2025-18 TH July 2025	19 weeks 6 days	<i>Ksheeranda Basti</i> -130ml (Ksheera-100ml + Anda/egg -30ml) and <i>Anuvasana Basti</i> with <i>ksheerabala taila</i> 45ml in <i>yoga basti</i> pattern Orally-BVC vati 1 OD A/F Tab Ecosprin 75MG	8 days 15 days

		Fe and ca suppliments	
Follow up scan- 20 th August 2025	A single intrauterine pregnancy corresponding to 25weeks 1 day. Doppler shows negative for PIH. EFW-748gram+-111grams Liquor-14.1cm		
25 TH Sep 2025 – 2 ND Oct 2025	31weeks 1 day	<i>Ksheeranda basti</i> -130ml (Ksheera-100ml+Anda/egg-30ml) and <i>anuvāsana basti</i> with <i>ksheerabala taila</i> 45ml in <i>yoga basti</i> pattern	8 days
Growth scan- 17 TH October 2025	A Single Intrauterine Pregnancy corresponding to 32weeks 4 day. EFW-2005gram+-300grams Liquor-14.1cm		
8 th Nov 2025 -16 th Nov 2025	37 weeks 2 days	<i>Mātrā basti</i> with <i>sukha prasava ghr̥ta</i> 40ml <i>Yoni pichu</i> with <i>Kṣīrabala taila</i>	9 days

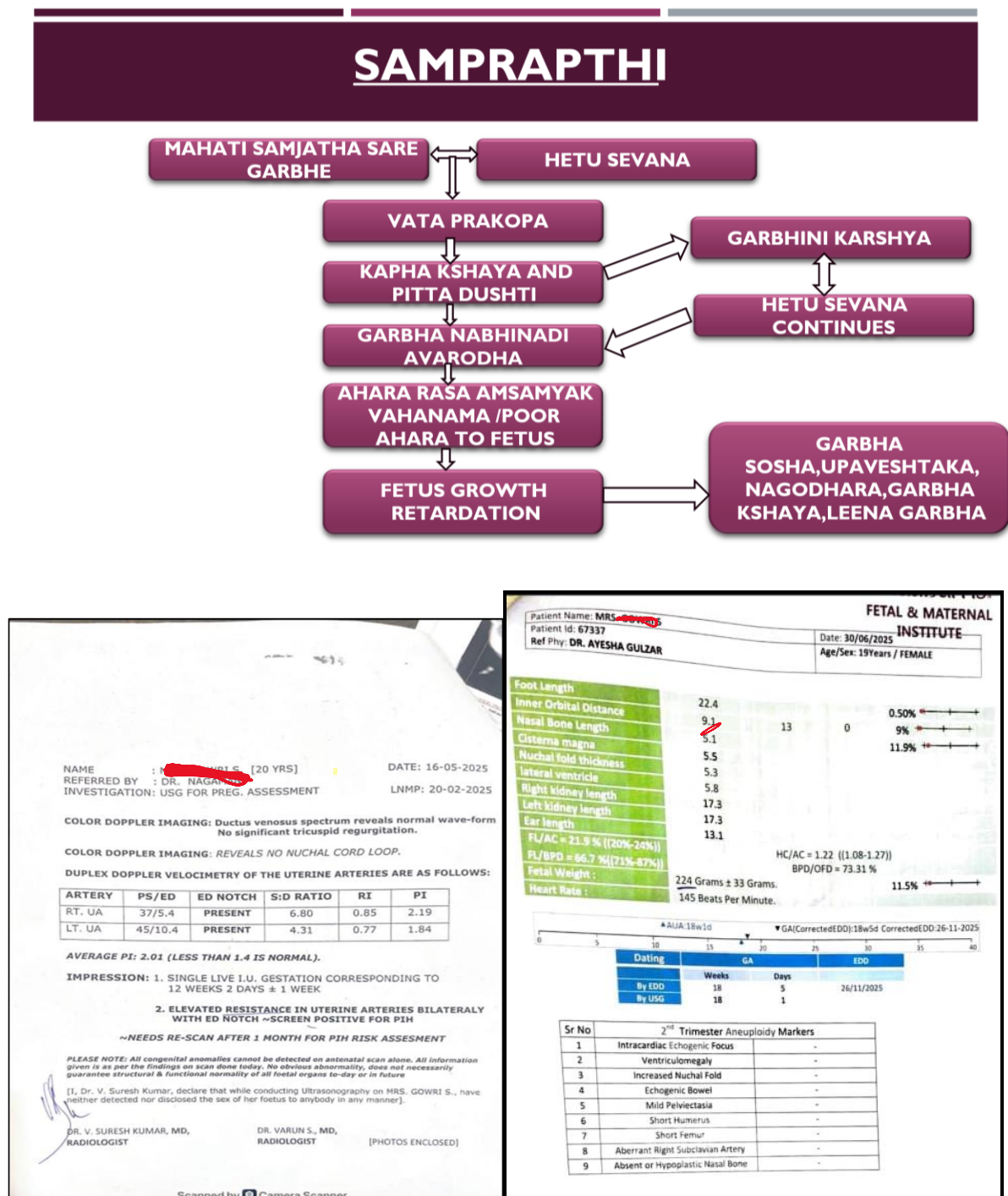
OBSERVATIONS AND RESULTS

Following initiation of the first course of *Kṣīrāṇḍa Basti* along with *Anuvāsana Basti* with *Ksheerabala taila* administered at 20 weeks along with tab Bruhat vata Chintamani rasa was given orally for 15 days and the patient exhibited gradual improvement in appetite (*Agnidīpana*) and normalization of bowel movements (*Mala Pravṛtti*) within 2–3 days, indicating effective *Vātānulomana*. Fifteen days after completion of the first *Basti* course, maternal body weight increased from 34 kg to 36 kg, suggesting improvement in *Rasa Dhātu* and an overall *Bṛṃhaṇa* effect. Follow-up ultrasonography demonstrated satisfactory *Garbha Poṣaṇa*, with an increase in estimated fetal weight from 243 g to 773 g.

A second course of *Kṣīrāṇḍa Basti* along with *Anuvāsana Basti* with *ksheerabala taila* administered at 31 weeks of gestation resulted in further enhancement of maternal nourishment, with maternal body weight increasing to 44 kg after treatment. Subsequently, *Mātrā Basti* with *Sukha Prasava Ghr̥ta* and *Yoni Pichu* with *ksheerabala taila* were administered after 37 weeks of gestation to facilitate *Vātānulomana* and *Sukha Prasava*. By term, maternal body weight reached 46 kg, and ultrasonography revealed an estimated fetal weight of 2005 g.

Considering the maternal pre-pregnancy body mass index and nutritional status, an expected fetal birth weight of approximately 2.5 kg was anticipated. At 39 weeks of gestation, the patient delivered vaginally a single live male baby weighing 2.5 kg on 19/11/2025. The

achieved neonatal birth weight indicates satisfactory *Garbha Poṣaṇa* and an effective *Bṛṃhaṇa* response to the instituted *Basti*-based Ayurvedic management.



RATHNA DIAGNOSTIC CENTRE
 * ULTRASOUND SCANNING WITH COLOUR DOPPLER * LABORATORY * X-RAY * ECG * ENDOSCOPY
 No.87/A, 7th Main, 30th Cross, 4th Block, Jayanagar, Bangalore - 560 011
 Phones : Off. 26549936, 22442683, Res.: 26644477
Dr. V. [Signature] UMAR, MBBS, MD (RD), Radiologist & Ultrasonologist
 Medical Director
 Consulting Hours :
 Week Days : 8.30 a.m. to 9.00 p.m. Sunday : 8.30 a.m. to 1.00 p.m.
 NAME : MRS. GOWRI S. [20 YRS] DATE: 20-08-2025
 REFERRED BY : DR. ANUPAMA V.
 INVESTIGATION: USG FOR PREG ASSESSMENT LNMP: 20-02-2025

There is single live intra-uterine gestation.
 Placenta is implanted high in the left antero-lateral wall & fundus.
 Grade '0' maturity is noted. No haematoma.
 Liquor amnii is normal in volume AFI: ~14.1 cm.
 An active foetus is seen showing brisk movements. Its cardiac activity is normal (FHR ~157/min). Foetal tone is normal.
 The foetal Cranium, Spine, four chamber view of the Cardia, Stomach, Kidneys, Urinary bladder and all four limbs are noted. No cleft lip or Talepes is noted. No obvious foetal anomaly is noted.

Nasal bone : 7.6 mm
 BPD : 65 mm
 OFD : 82 mm
 Cephalic Index : 81 %
 HC : 232 mm
 FL : 47 mm
 Gestational age : 25 weeks 1 day
 Abd. Circumference : 191 mm
 Est. Foetal weight : 748 grams [± 111 grams]
 EDD : 02-12-2025 ± 2 WKS
 Cervix is 3.6 cm in length & internal Os is closed.

[PTO]

RATHNA ULTRASOUND SCANNING CENTRE
 No. 87/A, 7th Main, 30th Cross, 4th Block, Jayanagar, Bangalore - 560 011
 Phones : Off. 26549936, 22442683, Res.: 26644477
Dr. V. [Signature] KUMAR, MBBS, MD (RD), Radiologist & Ultrasonologist
 Consulting Hours : 10.00 a.m. to 2.00 p.m. & 7.00 p.m. to 9.00 p.m.

NAME : MRS. GOWRI S. [20 YRS] DATE: 17-10-2025
 REF. BY : DR. ANUPAMA V.
 INVESTIGATION: USG FOR PREG. ASSESSMENT LNMP: 20-02-2025

There is single live intrauterine gestation.
 Placenta is implanted HIGH in the right anterior wall & fundus.
 Grade 'II' maturity (occasional calcification) is noted.
 Liquor amnii is normal in volume with AFI: 13.7
 An active foetus is seen in VERTEX - LOP presentation. Foetal cardiac activity is normal [FHR: 148 beats / min].
 Foetal tone is normal. The foetal cranium, spine, four chamber view of cardia, stomach, kidneys, urinary bladder & limbs are noted. Respiratory movements are seen.

BIO-PHYSICAL PROFILE SCORE: 8/8.
 BPD : 85 mm
 OFD : 103 mm
 Cephalic Index : 82 %
 HC : 300 mm
 Femoral length : 62 mm
 Gestational age : 32 weeks 4 days
 Abd. Circumference : 282 mm
 Est. foetal weight : 2005 gm [± 300 gm]
 EDD : 08-12-2025 ± 2 WKS
 Cervix: 3.6 cm long and internal os is closed.

[PTO]

INVESTIGATION

BLOOD INVESTIGATIONS		
	Blood group and Rh factor	O Positive
8/5/2025	HB	11.2%
20/7/25		10.6%
20/7/2025	TSH	3.35 microIU/ml
20/7/25	RBS	70mg/dl

DISCUSSION

According to Ayurvedic principles, inadequate intake of proper nutrition (*Ahāra*) leads to aggravation of *Vāta Doṣa*. Due to aggravated *Vāta*, *Ahāra Rasa* is not formed adequately, resulting in improper nourishment of the *Rasavahā Nāḍī* supplying the fetus. Obstruction in the *Rasavahā Nāḍī* causes impaired flow of *Rasa Dhātu*, leading to defective *Garbha Poṣaṇa*. Consequently, the fetus fails to develop normally and may manifest conditions described as *Upaviṣṭaka* or *Upaśuṣka*. The classics explain this pathology using the analogy of a paddy field, where crops do not grow properly if the flow of water is obstructed by leaves or grass, despite the presence of fertile land.^[1]

Further, the classics describe that women who frequently observe fasting, consume stale food, avoid unctuous substances, and indulge in *Vāta-prakopaka* regimens give rise to fetal desiccation and growth retardation. Such a fetus does not show proper movements, remains in the uterus for a prolonged duration, and fails to attain normal development. This condition is termed as *Nāgodara*. These descriptions clearly indicate the pivotal role of *Vāta* vitiation and *Rasa Dhātu Kṣaya* in the pathogenesis of fetal growth restriction.^[2]

Although *Basti* and other *Pañcakarma* procedures are generally contraindicated during pregnancy due to safety concerns, Ayurvedic classics permit the administration of specific and carefully selected *Basti* therapies during appropriate stages of gestation. *Suśruta* recommends the use of *Kṣīra Basti* during the eighth month of pregnancy along with intake of *Snigdha* and *Medhya* food for promoting maternal strength and fetal nourishment. This highlights the classical acceptance of milk-based and unctuous *Basti* therapies during advanced pregnancy.^[3]

Administration of *Basti* is generally avoided in the early months of pregnancy, especially during the first trimester, as the uterus is a pelvic organ and is more vulnerable to trauma, increasing the risk of abortion. After the fourth month, when the uterus ascends into the abdominal cavity and fetal stability improves, *Basti* therapy may be considered if clinically indicated. In the fifth month, carefully administered *Anuvāsana Basti* and *Kṣīra Basti* help pacify aggravated *Vāta*, enhance *Rasa Dhātu*, and improve *Garbha Poṣaṇa*, when performed under expert supervision.^[4]

Rasaushadhis are considered superior to any type of *Bheshaja prayoga* or *shastra prayoga*. *Bruhat vata chintamani Rasa* given during pregnancy has shown no adverse effects on the fetus or the mother. Hence, this formulation given in appropriate dose is safe and has excellent outcomes in pregnancy. Further, it may also help in *Buddhi* and *Medha Vardhana* in *Shishu* by the *swarnamruta* effect in *Garbhavastha* itself.

Based on *Charaka* and *Kashyapa* references, *Āmāgarbha* is described as beneficial in *Garbhaśoṣa*, promoting *garbhavṛddhi* and nourishment; *Āmāgarbha* here denotes *aṇḍa*, hence *kukkutāṇḍa* is selected. *Kāśyapa* further states that *dugdha* renders the *garbha puṣṭa* and *ṛddha*. Therefore, *Kukkutāṇḍa–Kṣīra Basti*^[5] (raw beaten egg with cow's milk) was administered and *ksheerabala taila*^[6] was used because of its *madhura rasa, snigdha*

guna, sheeta virya and *madhura vipaka* contributing to nourishment and strengthening of maternal tissues.

In the ninth month of pregnancy, administration of Anuvāsana Basti is advocated to provide strength to the mother, relieve stiffness and tension in the pelvic region, and facilitate *Vātānulomana*, thereby aiding preparation for labor.

Sukha Prasava Ghrita^[7] used for matra basti has *madhura rasa, snigdha guna, sheeta veerya*, and *madhura vipaka*. It pacifies *Apana Vata*, softens the cervix and birth passage, and improves tissue lubrication. Thus, it facilitates smooth and uncomplicated normal labor.

Vatahara property of *Balamula* and *Ksheera* helps in balancing the *Apana vata* and promotes its garbhanishkramana karma. hence prevents the undue prolongation of labor as well as prevents soft tissue obstruction in pelvic floor.

In the present case, appropriately selected Basti therapies played a significant role in improving maternal nutrition, regulating *Vāta Doṣa*, and supporting normal fetal growth. The observed improvement in maternal weight gain, progressive increase in fetal weight, and successful vaginal delivery of a healthy neonate support the classical rationale of Basti as an effective *Bṛmhaṇa* and *Vātahara* intervention during pregnancy when used judiciously.

CONCLUSION

This case report highlights the beneficial role of Ayurvedic Basti therapies in the management of underweight pregnancy. The use of Basti therapies contributed to improved maternal weight gain, regulation of Vata, and adequate fetal nourishment. The integrative application of Garbhini Paricharya supported normal fetal growth, cervical ripening, and smooth labor, resulting in a healthy full-term neonate without complications. These findings suggest that appropriately selected Basti therapies administered with due care can be a safe and effective supportive approach in undernourished pregnant women.

REFERENCE

1. Tiwari P. Prasūti Tantra. Vol. 1. 2nd Ed. Varanasi: Chaukhambha Orientalia, 1999. Reprint 2003; P. 363.
2. Tiwari P. Prasūti Tantra. Vol. 1. 2nd Ed. Varanasi: Chaukhambha Orientalia, 1999. Reprint 2003; P. 364.

3. Murthy Srikantha K.R(Editor). Sushruta Samhita Of Sushruta,Sharirastana, Chapter 10, Verse No.4, Vol I, Reprint Edition, Varanasi;Chaukhamba Orientalia, 2017; 23.
4. Singh S. Basti therapy: Regulating Vata dosha for a healthy pregnancy. Int J Educ Appl Sci Res, 2021; 8(1): 11–22. EISSN 2349-2899. ISSN 2349-4808.
5. Tiwari P. Prasūti Tantra. Vol. 1. 2nd Ed. Varanasi: Chaukhambha Orientalia, 1999. Reprint 2003; P.368.
6. R Vidyanath, K Nishteshwar. Sahasra Yoga. 2nd ed.Varanasi: Chaukhambha Sanskrit Series Office;2008.Taila Prakarana, p.110-12.
7. Kaikkuangara rama warrier, Arogyakalpadrumam sanskrit text with english translation by prof Dr. K. Muraleedharan pillai pulblised by sahithi books, Kerala-2018, 46th chapter, verse-47-48, pg-409.