

## **A REVIEW ON ALTERNATIVE MEDICINE USING HOMEOPATHY SYSTEM FOR TREATMENT OF LOSS OF HAIR**

**Mohd. Wasiullah<sup>1</sup>, Piyush Yadav<sup>2\*</sup>, Prithvi Raj Chauhan<sup>3</sup> and Vinay Kumar Deepak<sup>4</sup>**

<sup>1</sup>Principal, Dept. of Pharmacy, Prasad Institute of Technology, Jaunpur (222001) U.P, India.

<sup>2</sup>Principal, Dept. of Pharmacy, Prasad Polytechnic, Jaunpur (222001) U.P, India.

<sup>3</sup>Dept. of Pharmacy, Prasad Institute of Technology, Jaunpur (222001) U.P, India.

<sup>4</sup>Assistant Professor, Dept. of Pharmacy, Prasad Institute of Technology, Jaunpur (222001) U.P, India.

Article Received on  
13 Nov. 2022,

Revised on 03 Dec. 2022,  
Accepted on 23 Dec. 2022

DOI: 10.20959/wjpr20231-26732

### **\*Corresponding Author**

**Piyush Yadav**

Principal, Dept. of  
Pharmacy, Prasad  
Polytechnic, Jaunpur  
(222001) U.P, India.

### **ABSTRACT**

Hair loss not only hereditary and age-related but can be the first sign of medical disorder like anaemia, hypothyroidism, diabetes, polycystic ovaries, stress and other. Alopecia areata (AA) is an autoimmune disease characterised by non-scarring hair loss in single or multiple areas of the scalp. The disease affects hair on the head or other parts of the body. AA occurs in people of all ages and affects 1-2% of human population. Homoeopathic literature shows that cases of AA have been treated successfully with homoeopathic medicines. A 15 years old boy presented with clinically diagnosed Alopecia areata condition at OPD, Govt Homoeo-Dispensary, Panjal, Kerala. The patient was treated with

individualized homeopathic medicine for 1 year. There was a complete cure of Alopecia areata without any side effects and recurrence of lesions. Individualized homeopathic medicine selection after considering totality of symptoms proves worth. This case report supports the positive role of homoeopathy in treating alopecia areata.

**KEYWORDS:** Alopecia areata (AA), hair loss, Autoimmune disease, Homoeopathy.

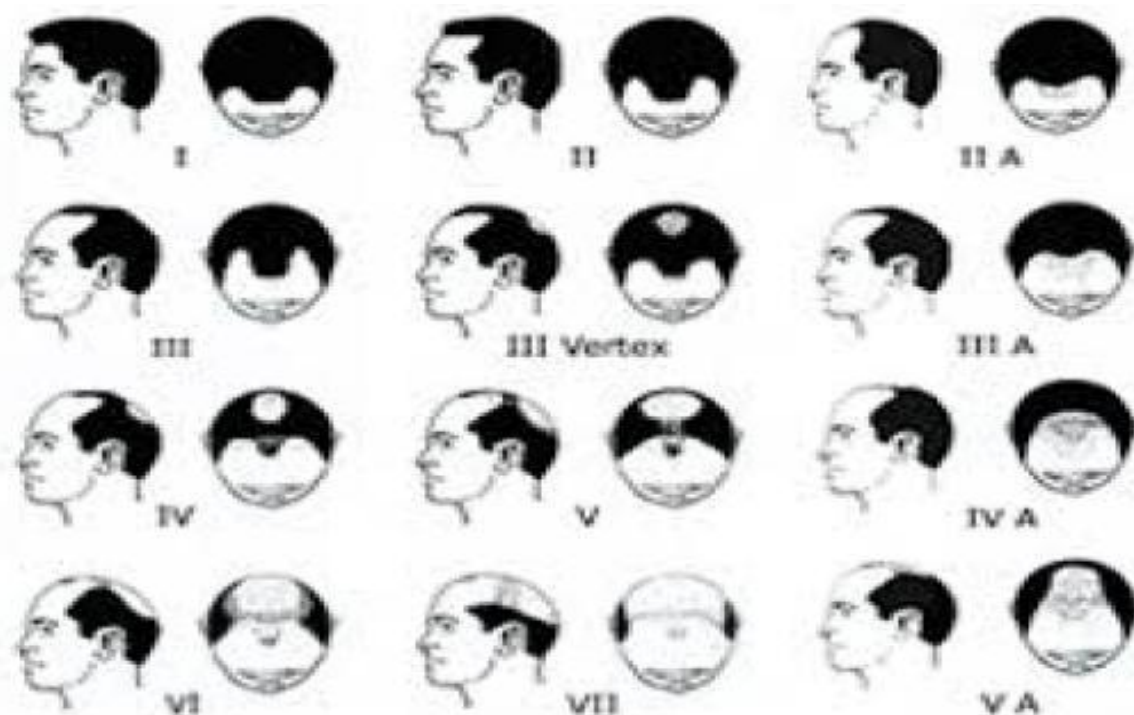
### **INTRODUCTION**

Alopecia areata (aa) is an autoimmune disorder characterized by patches of non-scarring hair loss affecting scalp and body hair. This condition may affect the eyebrows, eyelashes and beard.<sup>[1]</sup> aa is the most prevalent autoimmune disorder and the second most prevalent hair loss disorder after androgenetic alopecia. The lifetime incidence of aa is approximately 2%

worldwide.<sup>[2]</sup> The disease may be limited to one or more discrete, well-circumscribed, round, or oval patches of hair loss on the scalp or body. But in some cases, it may affect the entire scalp is known as alopecia totalis or the entire body is known as alopecia universalis.<sup>[3]</sup> In diffuse alopecia areata cases prognosis may be bad.<sup>[4]</sup> In most patients the onset is within the first 3 decades of life, although alopecia areata can start any age. The sex incidence is probably equal.<sup>[5]</sup> Psychosocial stress has been reported to play a role in the onset and/or exacerbation of alopecia areata.<sup>[6]</sup> AA is associated with psychiatric and medical comorbidities including depression, anxiety, and several autoimmune disorders. Diagnosis is made by Clinical history, the pattern of alopecia, clinical examination, in diffuse cases, trichogram and biopsy are advised.<sup>[7]</sup> In conventional medicine there is no preventative therapy or cure and it is increased global burden of disease, a systematic review on epidemiology and burden of alopecia areata had concluded. Whereas the homeopathy system of medicine will offer promising results in the treatment of alopecia areata with individualized homeopathic medicine, and also it can treat root cause to prevent recurrence and ensure healthy hair growth. This case report further provides evidence for individualized homeopathic medicine effectiveness in the treatment of alopecia areata. Hair, our crowning glory, not only represents beauty, power and strength but much more. A study showed that 41% of men with full heads of hair were selected for job interviews compared to only 27% of balding men rejection at work and marriage can result in loss of self-esteem and can even lead to depression and suicide 25% of men do experience hair loss before they attain the age of 21 (Figures 1 and 2).



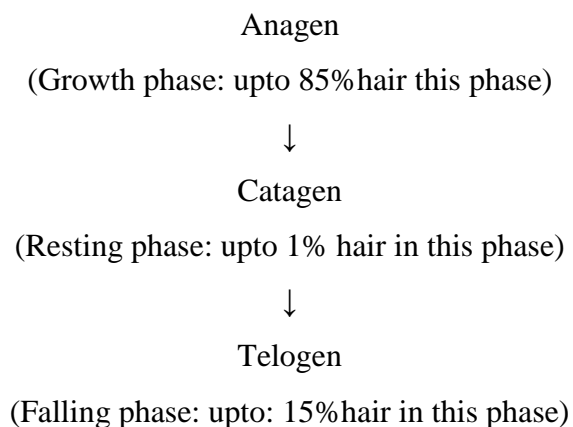
**Figure 1: Hair loss affects the genders in women.**



**Figure 2: Hair loss affects the genders in men.**

Hair loss can affect both the genders in men and in women. It is estimated that 13% of women suffer from baldness before they menopause stage.<sup>[1,2]</sup>

### Normal hair cycle



### CASE REPORT

A 15 years old boy consulted at OPD of Govt. Homeo-Dispensary, Panjab, Kerala, with multiple hair loss patches over the scalp. Complaints started at the age of 10 years as loss of hair over vertex region of the scalp, after that he was consulted a dermatologist, and taken some treatment, initially there was some regrowing of hair but after that, he had developed 2 more other lesions in occiput and frontal region of the scalp. The boy had a history of atopy

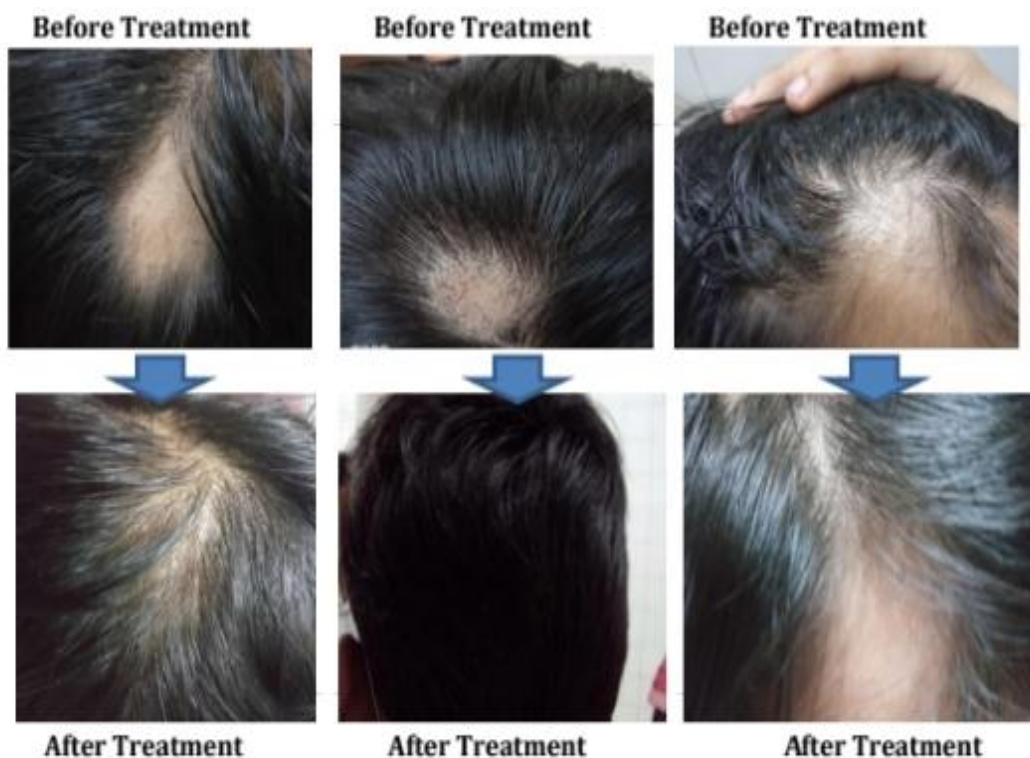in childhood, his skin was sensitive and dry, and he had dandruff with itching scalp. His parents were concerned about his condition tried conventional treatments but could not get benefit much. On local examinations, hair loss patches were present over the scalp, multiple patches on vertex, frontal, and occiput region, and on close examination, there were short broken hair present at the edge of patches which are known as 'exclamation mark'. With the history, pattern of hair loss and pathognomonic feature of exclamation mark on examination lead the diagnosis of alopecia areata. 15<sup>th</sup> October 2019 was his first consultation, specific remedy for alopecia areata selenium 30c was given weekly once for 1 month. But no positive change was noted, after that detailed case taking was done. The boy was social, wants company, talkative and bold, but sensitive to trifles and offends easily, anxiety about alopecia condition, has fear of thunderstorm, average in studies, desire fish and chicken but chicken causes urticarial rashes over the skin, his perspiration was profuse which leaves yellow stains on innerwear and his thermal reaction was chilly.

### **Methodology/Treatment given**

All the symptoms obtained from detailed case taking were analyzed as in table no.1, characteristic symptoms were converted to rubrics, Kent repertory was selected for repertorization, and is done through similimum ultra software as in table no.2. On 20/11/2019 has been given Phosphorus 0/3, 1dose, OD in the morning for 1 month. Phosphorus Medicine was selected based on individualization, repertorization and in consultation with Materia medica.<sup>[8-9]</sup> Along with medicine diet and regimen also recommended and advised some exercises, relaxation techniques to relieve stress. On subsequent follow-ups, potency was changed based on the assessment of improvement in bald patches. Follow-up of the patient was assessed monthly or as required. The date-wise detailed follow-ups are summarized in Table no.3. No adverse effects were noted during the period treatment.

### **RESULTS**

The bald patches on the head showed new hair growth. Initially, Phosphorus 0/3 showed improvement. However, much significant improvement was observed with higher potency Phosphorus 0/6, 0/12. Bald patches on the head completely disappeared within 1 year of homeopathic treatment (Figures 3-5).

**Figure 3:****Figure 4:****Figure 5:**

## DISCUSSION

The patient presented with multiple bald patches on the head. There was no family history of AA or other autoimmune complaint in the family. This case treated with individualized homoeopathic drug showed complete hair re - growth without any rush in a follow - up period. As there's no effective treatment in conventional drug, a substantial number of AA cases resort to CAM. Itamura<sup>[10]</sup> reported an Alopecia universalis case treated with Mercurius with significant enhancement. Willemsen et al<sup>[11]</sup> used hypnotism to treat AA. In this case, after careful history recording, reports and discussion with Materia Medica, Lycopodium drug was specified. The case showed enhancement in the morning which proved correct selection of the drug, but there was slow enhancement with low - energy Lycopodium 30C. still, pronounced enhancement was observed with advanced 1M energy. This case shows the effective part of homoeopathic drug in treating AA when specified on the base of homoeopathic principles.

## CONCLUSION

Homoeopathy is a system of medicine based on the principle of ‘Similia Similibus Curentur’. It treats patient as a whole and not just symptoms. After careful case taking, analysis and repertorization done systematically, then the selection of the right medicine with



a suitable scale of potency and dosage results in remarkable cures. Complete hair re-growth and without any recurrence of bald patches in observation period is documentary evidence. This case showed a positive role of Homoeopathy in treating Alopecia areata. this is a single case study and AA is associated with a variable and unpredictable remission,<sup>[12]</sup> well-designed studies may be taken up for scientific validation of results.

## REFERENCES

1. Davidson's Principles and practice of medicine, edi. Nicholus AB, Nicki RC, Brain RW, 20th edition, Churchill Livingstone/Elsevier, Edinburgh, 2010; 1278.
2. Alexandra C Villasante Fricke AC, Miteva M. Epidemiology and burden of alopecia areata: A systematic review. Clin Cosmet Investig Dermatol, 2015; 8: 397-403.
3. Arthur R, Rook's textbook of dermatology, Edi. Tony, Stephen b, Neil c, Christopher G, Eighth edition, John Wiley Sons, 2010; 4, 66: 66.31-66.38.
4. Shivakumar K, Hair problems answered with homoeopathy, Alopecia Areata, B.jain: New Delhi, 2016; 46-75.
5. Klaus W, Lowel AG, Stephen IK, Barbara AG, Amy SP, David JL, Fitzpatrick's dermatology in medicine, Mc graw hill, USA, 2008; 7: 1 - 762.
6. Gupta MA, Gupta AK, Watteel GA Stress and alopecia areata: a psychodermatologic study, Acta Dermato-venereologica, 1997; 77(4): 296 -298.
7. Rivitti EA. Alopecia areata: A revision and update. Bras Dermatol, 2005; 80: 57-68.
8. Boericke W. Pocket manual of homoeopathic materia medica and repertory. B. Jain, New Delhi, 1994; 507.
9. Allen HC, Key notes and characteristics with comparisons of some of the leading remedies of the materia medica with bowel nosodes, Eighth edition, B.Jain: New Delhi, 2002; 219.
10. Itamura R. Effect of homeopathic treatment of 60 Japanese patients with chronic skin disease. Complement Ther Med, 2007; 15: 115-20.
11. Willemsen R, Vanderlinden J, Deconinck A, Roseeuw D. Hypnotherapeutic management of alopecia areata. J Am Acad Dermatol, 2006; 55: 233-7.
12. Harries MJ, Sun J, Paus R, King LE Jr. Management of alopecia areata. BMJ, 2010; 341: c3671.